

1 **Title page**

2 **Title:** Negative Nasopharyngeal and Oropharyngeal Swab Does Not Rule Out COVID-19

3 Poramed Winichakoon, M.D.<sup>1</sup>, Romanee Chaiwarith, M.D.<sup>1</sup>, Chalerm Liwsrisakun, M.D.<sup>2</sup>, Parichat  
4 Salee, M.D.<sup>1</sup>, Aree Goonna, M.N.S.<sup>3</sup>, Atikun Limsukon, M.D.<sup>2</sup>, Quanhathai Kaewpoowat, M.D.<sup>1,4\*</sup>

5

6 **Affiliation:**

7 <sup>1</sup> Division of Infectious Diseases and Tropical Medicine, Department of Medicine,  
8 Faculty of Medicine, Chiang Mai University, Chiang Mai, Thailand

9 <sup>2</sup> Division of Pulmonology and Critical Care, Department of Medicine,  
10 Faculty of Medicine, Chiang Mai University, Chiang Mai, Thailand

11 <sup>3</sup> Infection Control Unit, Maharaj Nakorn Chiang Mai Hospital, Chiang Mai University,  
12 Chiang Mai, Thailand

13 <sup>4</sup> Research Institute for Health Sciences, Chiang Mai University, Chiang Mai, Thailand

14

15 **Corresponding Author:** Quanhathai Kaewpoowat, M.D.

16 Division of Infectious Disease and Tropical Medicine,  
17 Department of Medicine,

18 Faculty of Medicine, Chiang Mai University, Thailand 50200

19 Phone: +66-53-936457

20 e-mail: quanhathai@rihes.org

21

22

23

24

25 Dear the Editor,

26 Coronavirus Disease 19 (COVID-19), has become the Public Health Emergency of  
27 International Concern. The diagnosis is made by the detection of novel virus or genetically similar  
28 coronavirus by molecular assay in clinical specimens<sup>1</sup>. Nasopharyngeal and oropharyngeal (NP/OP)  
29 samples are commonly used as a screening tool. Here we reported a case of COVID-19 pneumonia  
30 diagnosed from bronchoalveolar lavage (BAL) fluid who initially had negative tests from NP/OP  
31 swabs.

32 On 21 January 2020, a 28-year-old previously healthy Chinese man presented to Maharaj  
33 Nakorn Chiang Mai Hospital, Chiang Mai, Thailand, with a 3-day history of high grade fever and  
34 malaise. He also complained of rhinorrhea and cough, which had already resolved. He traveled from  
35 Jinzhou, China to Chiang Mai on January 15, 2020 by trains and airplanes with a brief transit in  
36 Wuhan. After his full itinerary was identified, his case was reported to the local government health  
37 agency as a patient under investigation for COVID-19. He was admitted to airborne infection isolation  
38 room and NP/OP swabs were obtained. The specimens were sent to two reference laboratories (the  
39 Thai Red Cross Emerging Infectious Diseases Health Sciences Center, Faculty of Medicine,  
40 Chulalongkorn University, and the Department of Medical Sciences, Ministry of Public Health) which  
41 tested negative for SARS-CoV-2 on real-time reverse-transcriptase–polymerase-chain-reaction (RT-  
42 PCR) assay<sup>1</sup>. His chest radiography on hospital day 3 did not reveal any infiltration. He continued to  
43 be febrile without other respiratory symptoms. On hospital day 5 the NP/OP swabs were repeated and  
44 were again reported as negative for SARS-CoV-2. On hospital day 7, he developed non-productive  
45 cough. The chest radiography revealed bilateral lower lung infiltrations with prominent on the right  
46 (Fig 1), which was compatible with viral pneumonia. Bronchoscopy and BAL was performed on  
47 hospital day 8 and BAL fluid was tested positive for SARS-CoV-2 by RT-PCR. On hospital day 10,  
48 his overall clinical condition improved with increasing appetite and afebrile. He was discharged on  
49 hospital day 18.

50 Our case highlighted the importance of high clinical suspicion in the epidemiological matched patient  
51 who had negative NP/OP swab. While most of the reported cases established the diagnosis from NP

52 /OP swab, it is possible that NP/OP could yield the false negative result. Several factors might have  
53 contributed to the false negative results, including but not limited to the sampling technique,  
54 transportation process, or limited gene(s) detection, however it could also be explained by the nature  
55 of coronavirus itself. This finding was previously observed in previous SARS<sup>2</sup> and MERS<sup>3</sup> outbreaks.  
56 It is supported by the basic science evidence that the target functional receptor of these viruses is  
57 angiotensin-converting enzyme 2 (ACE2)<sup>4,5</sup>. Surface expression of ACE2 was found abundantly on  
58 both type I and type II alveolar epithelial cells, but minimally on bronchial epithelial cells and  
59 negative on nasal, oral, and nasopharynx. Based on the case presentation above, we strongly  
60 recommend the clinicians to continue keeping the suspicion of COVID-19 infection in the  
61 epidemiological linked patient despite negative NP/OP result.

- 62 1. World Health Organization. Novel Coronavirus (2019-nCoV) technical guidance: Laboratory  
63 testing for 2019-nCoV in humans. ([https://www.who.int/emergencies/diseases/novel-coronavirus-](https://www.who.int/emergencies/diseases/novel-coronavirus-2019/technical-guidance/laboratory-guidance)  
64 [2019/technical-guidance/laboratory-guidance](https://www.who.int/emergencies/diseases/novel-coronavirus-2019/technical-guidance/laboratory-guidance)).
- 65 2. Peiris JS, Chu CM, Cheng VC, et al. Clinical progression and viral load in a community  
66 outbreak of coronavirus-associated SARS pneumonia: a prospective study. *Lancet* (London, England)  
67 2003;361:1767-72.
- 68 3. Memish ZA, Al-Tawfiq JA, Makhdoom HQ, et al. Respiratory tract samples, viral load, and  
69 genome fraction yield in patients with Middle East respiratory syndrome. *The Journal of infectious*  
70 *diseases* 2014;210:1590-4.
- 71 4. Hamming I, Timens W, Bulthuis ML, Lely AT, Navis G, van Goor H. Tissue distribution of ACE2  
72 protein, the functional receptor for SARS coronavirus. A first step in understanding SARS  
73 pathogenesis. *The Journal of pathology* 2004;203:631-7.
- 74 5. Wan Y, Shang J, Graham R, Baric RS, Li F. Receptor recognition by novel coronavirus from  
75 Wuhan: An analysis based on decade-long structural studies of SARS. *Journal of virology* 2020.

76

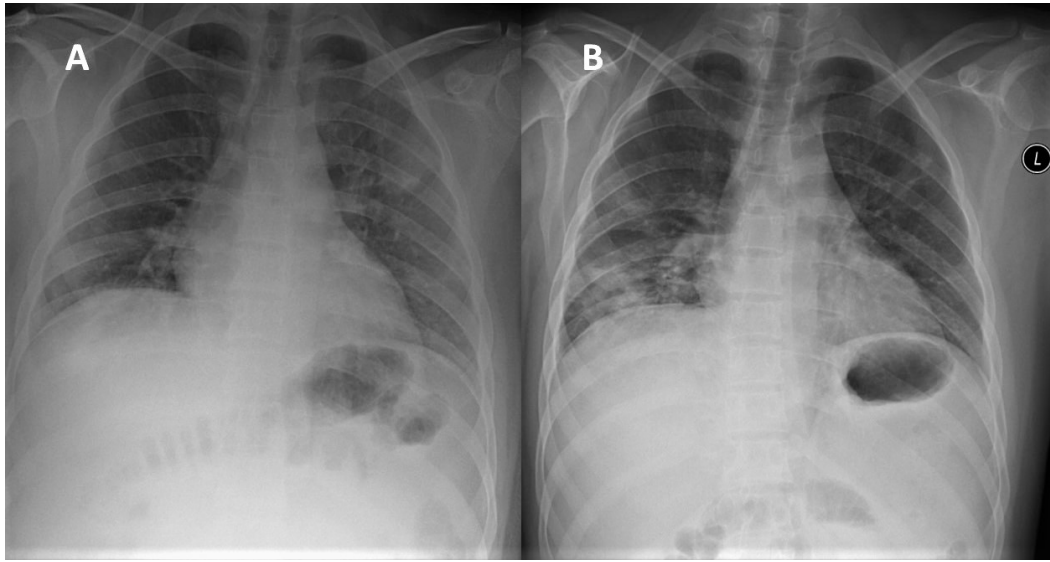


Figure 1. Chest Radiographs

A posteroanterior radiograph of the chest in the upright position of the patient on hospital day 3 (Panel A) shows no infiltration. A follow-up radiograph on hospital day 7 (Panel B) after the patient developed non-productive cough reveals new bilateral lower lung infiltrations, which are predominantly noticed on right lower lung zone.