



Since January 2020 Elsevier has created a COVID-19 resource centre with free information in English and Mandarin on the novel coronavirus COVID-19. The COVID-19 resource centre is hosted on Elsevier Connect, the company's public news and information website.

Elsevier hereby grants permission to make all its COVID-19-related research that is available on the COVID-19 resource centre - including this research content - immediately available in PubMed Central and other publicly funded repositories, such as the WHO COVID database with rights for unrestricted research re-use and analyses in any form or by any means with acknowledgement of the original source. These permissions are granted for free by Elsevier for as long as the COVID-19 resource centre remains active.



Disponible en ligne sur
ScienceDirect
www.sciencedirect.com

Elsevier Masson France
EM|consulte
www.em-consulte.com



Letter to the editor

SARS-CoV-2 infection presenting with hemochezia

ARTICLE INFO

Keywords:
SARS-CoV-2
COVID-19
Clinical symptoms

1. Introduction

The newly emergent coronavirus (2019-nCoV, now known as SARS-CoV-2) was first identified in Wuhan in December 2019 and spread rapidly to all provinces and cities in China [1]. Current research suggests that efficient transmission of SARS-CoV-2 from infected individuals (both symptomatic and asymptomatic) to uninfected contacts can result from respiratory droplets, aerosols, and direct contact. Other routes, including the fecal-oral and mother-to-child vertical transmission, have not been confirmed. The main clinical symptoms of SARS-CoV-2 infection (known as COVID-19) are fever, fatigue, and cough leading to pneumonia that can develop into acute respiratory distress syndrome [2,3]. There are currently several documented cases of

patients diagnosed with COVID-19 that had digestive findings as the first sign of disease [4]. We present a case of COVID-19 that presented to our hospital with a chief complaint of hemochezia.

2. Case report

An 83-year-old man presented with chief complaint of dark-red bloody stools. He reported stool volume of approximately 200 mL 2–3 times per day, fatigue, and poor appetite beginning one day prior to presentation. He was admitted to the Gastrointestinal Ward 1 of Luoyang Central Hospital on January 27, 2020 for evaluation and follow-up. At admission the patient was oriented but in low spirits. He was eating and sleeping poorly and was oliguric although no significant weight loss was observed.

On the second day of admission, the patient excreted bloody stools several times during the day. He received initial symptomatic treatment with oral pantoprazole enteric-coated capsule, once a day. Abdominal computerized tomography (CT) scan performed on the third day of admission suggested the presence of a space-occupying lesion at the right adrenal gland; the diagnosis of adrenal tumor was considered. As the patient was elderly and not specifically symptomatic, follow-up observation was recommended. A magnetic resonance imaging (MRI) examination revealed abnormal signals within the seminal vesicle, suggesting the possibility of internal hemorrhage; follow-up prostate MRI was recommended.

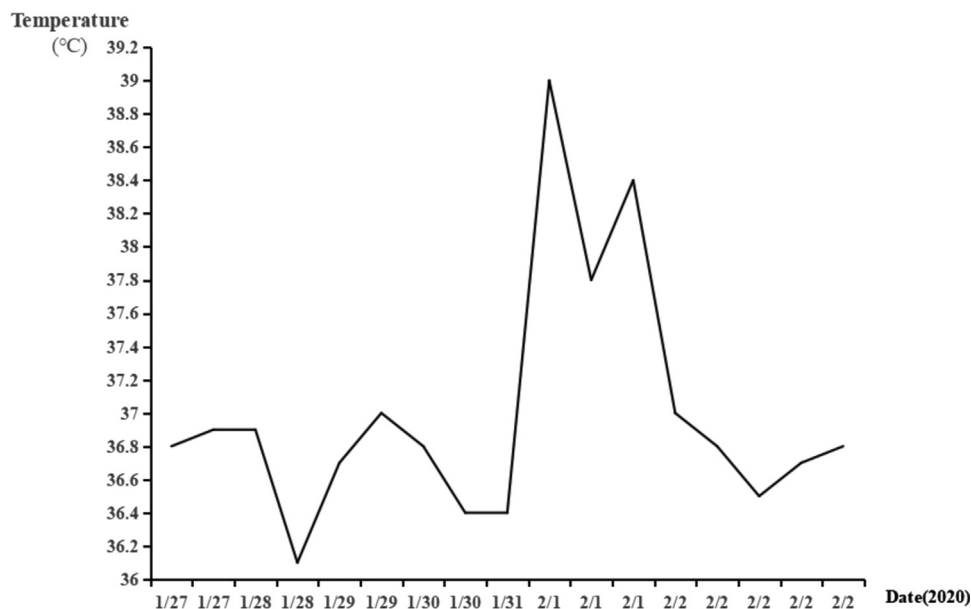

Fig. 1. Body temperature during hospital admission.

<https://doi.org/10.1016/j.medmal.2020.03.005>
0399-077X/© 2020 Elsevier Masson SAS. All rights reserved.

Table 1
Laboratory data including complete blood count (CBC).

Measure	Reference range	Hospital day 1	Hospital day 6
White blood cell count (10 ⁹ /L)	3.5–9.5	6.62	5.15
Red blood cell count (10 ¹² /L)	10–12	3.77 ^a	3.66 ^a
Absolute neutrophil count (10 ⁹ /L)	1.8–6.3	5.61	4.42
Absolute lymphocyte count (10 ⁹ /L)	1.1–3.2	0.73 ^a	0.36 ^a
Platelet count (10 ⁹ /L)	125–350	122 ^a	81 ^a
Hemoglobin (g/L)	130–175	115 ^a	110 ^a
Hematocrit (%)	40–50	34.6 ^a	32.4 ^a
C-reactive protein (mg/L)	0–10	/	21.78 ^b
Procalcitonin (ng/mL)	0–0.5	/	0.53 ^b
Type B natriuretic peptide (pg/mL)	0–100	49.44	108.7 ^b
Fibrinogen (g/L)	2–4	1.83 ^a	2.89
Prothrombin time (s)	9–13	13.7 ^b	10.8
International normalized ratio	0.76–1.24	1.21	0.96
Activated partial prothrombin time (s)	20–40	26.7	32.7
Thrombin time (s)	14–21	15.5	14.7
D-Dimers (ng/mL)	0–550	220	1.100 ^b

^a Values below normal range.^b Values above normal range.

Colonoscopy was also recommended to clarify the acute colorectal findings and to identify the source of bleeding.

On the fifth day of admission, the patient's condition remained stable. Colonoscopy revealed three polyps in the colon, but no tumors or hemorrhagic sites were identified. Therefore, hemochezia secondary to infection was considered. On this same day, the bloody stools disappeared, but the patient suddenly developed a fever, with peak body temperature measured at 39 °C (Fig. 1). The patient denied any symptoms including chest tightness, cough, expectoration, or dyspnea. The physical examination on this day was notable for bilateral rough breath sounds and moist rales in the lower right lung. He was treated with dexamethasone injection, and the fever disappeared.

Laboratory tests on and during admission revealed a white blood cell count within the normal range, but the number of lymphocytes and platelets as well as red blood cell count, hemoglobin, and hematocrit levels all decreased gradually during the hospital stay (Table 1). The rapid antigen test was negative for both influenza

A and B and blood cultures were negative. On hospital days six and seven, throat swabs obtained from the patient tested positive for SARS-CoV-2 by real-time RT-PCR. CT scan images on admission showed no abnormality (Fig. 2), but when repeated on the fifth day after admission, the CT scan revealed infiltrates in the lower right lung (Fig. 3).

Upon questioning, the patient disclosed his granddaughter had contact with people who had returned from Wuhan. This contact took place on January 23, 2020 and lasted for approximately 30 minutes. At that time, his granddaughter had no symptom, although his daughter had developed a fever but did not have any sign or symptom of pneumonia.

Based on the epidemiological history, detection of SARS-CoV-2 by real-time RT-PCR, and the chest CT scan findings, the patient was diagnosed with COVID-19. On his seventh day of admission, he was transferred to the first affiliated hospital of Henan University of Science and Technology for further evaluation and treatment.

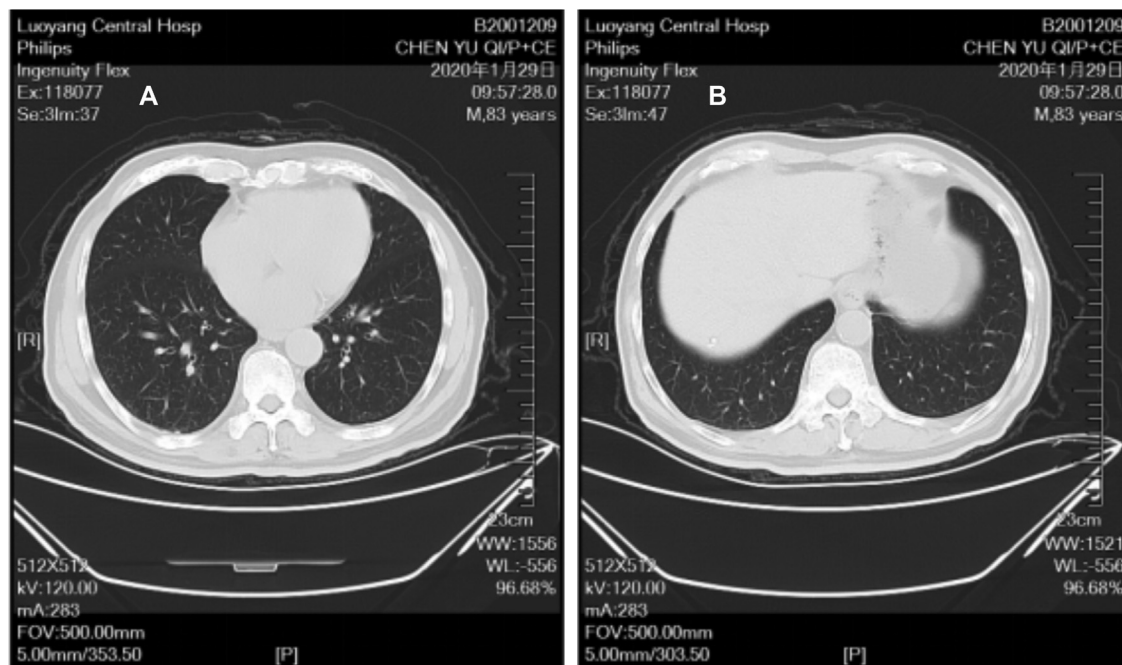


Fig. 2. A and B. On January 29, computerized tomography (CT) scan images revealed no acute intrathoracic abnormalities.

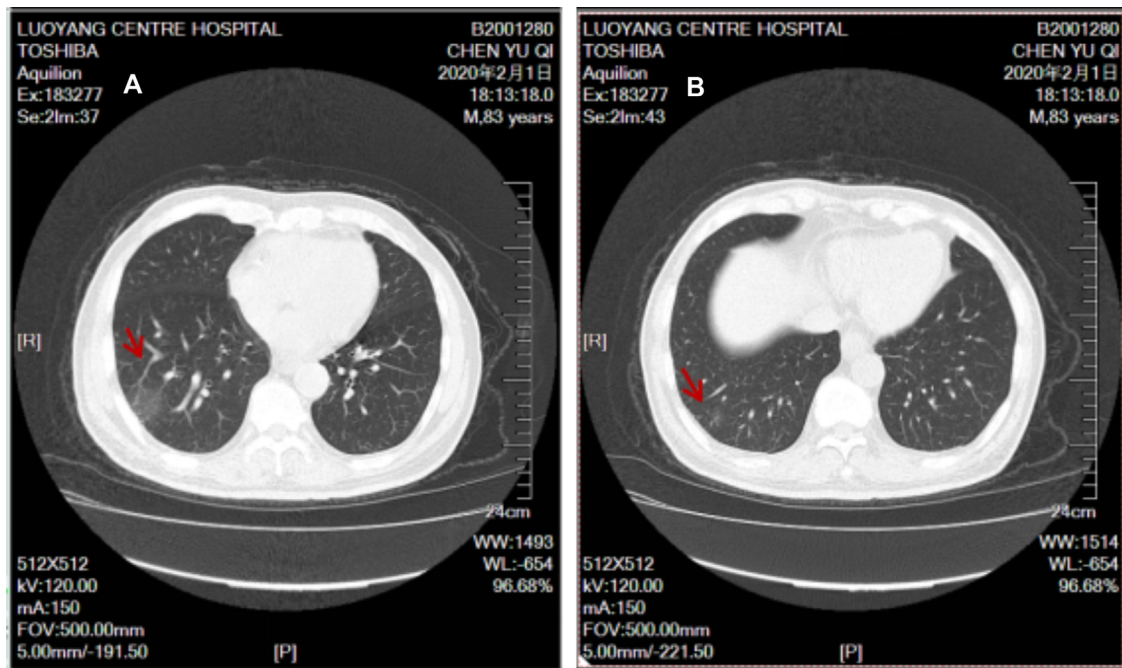


Fig. 3. A and B. On February 1, computed tomography (CT) scan images revealed a single ground-glass opacity in the right lower lung lobe.

3. Discussion

The patient was an 83-year-old man who developed hema-tochezia three days after indirect contact with individuals returning from Wuhan. Nine days later, he developed fever and lung inflammation with throat swabs that tested positive for SARS-CoV-2. As such, he was diagnosed with COVID-19. No source of bleeding was identified by colonoscopy or abdominal CT scan and as such, we considered the possibility that hema-tochezia might be secondary to infection with SARS-CoV-2 pathogen. Unfortunately, we did not determine whether SARS-CoV-2 could be detected in stool specimens, which may have provided further direct evidence in this case. At this writing, there are several reports of diarrhea associated with the presentation of SARS-CoV-2 infection [4], but to the best of our knowledge, this is the first report of hema-tochezia as the presenting symptom and chief complaint.

Upon diagnosis, the patient was transferred to the first affiliated hospital of Henan University of Science and Technology, and as such we have no additional follow-up information.

Six days after the patient left our hospital (February 7, 2020), another 63-year-old male patient – who had been on the same ward with underlying diagnoses of intestinal obstruction and postoperative recurrence of rectal carcinoma – developed fever and was also diagnosed with COVID-19. The ward was emptied and sterilized repeatedly; the Center for Disease Control (CDC) collected samples from numerous surfaces including the desk-top, bed sheets, and quilt covers. SARS-CoV-2 was detected on these surfaces even after repeated attempts at sterilization. These results suggest that these patients may have carried high viral loads.

Taken together, our findings with respect to this case patient suggest that fever and respiratory findings may not be the only presenting signs and symptoms of SARS-CoV-2 infection. Presentations including diarrhea and hema-tochezia may be secondary to an alternate point of entry. This point needs to be clarified as quickly as possible.

Human and animal rights

The authors declare that the work described has been carried out in accordance with the Declaration of Helsinki of the World Medical Association revised in 2013 for experiments involving humans as well as in accordance with the EU Directive 2010/63/EU for animal experiments.

Informed consent and patient details

The authors declare that this report does not contain any personal information that could lead to the identification of the patient(s) and/or volunteers.

Disclosure of interest

The authors declare that they have no competing interest.

Funding

This work did not receive any grant from funding agencies in the public, commercial, or not-for-profit sectors.

Author contributions

All authors attest that they meet the current International Committee of Medical Journal Editors (ICMJE) criteria for Authorship.

References

- [1] Patel A, Jernigan DB, 09-nCoV CDC Response Team. Initial public health response and interim clinical guidance for the 2019 novel coronavirus outbreak – United States, December 31, 2019–February, 4 2020. *J MMWR Morb Mortal Wkly Rep* 2020;69(5):140–6.
- [2] Special Expert Group for Control of the Epidemic of Novel Coronavirus Pneumonia of the Chinese Preventive Medicine Association. An update on the epidemiological characteristics of novel coronavirus pneumonia (COVID-19). *J Zhonghua Liu Xing Bing Xue Za Zhi* 2020;41(2):139–44.

- [3] Wang D, Hu B, Hu C, et al. Clinical characteristics of 138 hospitalized patients with 2019 novel coronavirus-infected pneumonia in Wuhan, China. *JAMA* 2020, <http://dx.doi.org/10.1001/jama.2020.1585>.
- [4] Wei-jie Guan, Zheng-yi Ni, Nan-shan Zhong, et al. Clinical characteristics of 2019 novel coronavirus infection in China. *J MedRxiv* 2020, <http://dx.doi.org/10.1056/NEJMoa2002032>.

L. Guotao^{a,1}
Z. Xingpeng^{a,1}
D. Zhihui^b
W. Huirui^{a,*}

^a *Infectious diseases department, Luoyang Central Hospital Affiliated to Zhengzhou University, Luoyang, Henan, China*

^b *Imaging department, Luoyang Central Hospital Affiliated to Zhengzhou University, Luoyang, Henan, China*

* Corresponding author.

E-mail addresses: wanghuirui7873@163.com,
lyszxykyk@163.com (W. Huirui)

¹ These authors equally contributed to this work.

Received 22 March 2020

Accepted 25 March 2020

Available online xxx