



Since January 2020 Elsevier has created a COVID-19 resource centre with free information in English and Mandarin on the novel coronavirus COVID-19. The COVID-19 resource centre is hosted on Elsevier Connect, the company's public news and information website.

Elsevier hereby grants permission to make all its COVID-19-related research that is available on the COVID-19 resource centre - including this research content - immediately available in PubMed Central and other publicly funded repositories, such as the WHO COVID database with rights for unrestricted research re-use and analyses in any form or by any means with acknowledgement of the original source. These permissions are granted for free by Elsevier for as long as the COVID-19 resource centre remains active.



Brief Communication

COVID-19 in a patient with long-term use of glucocorticoids: A study of a familial cluster



Yuanyuan Han^{a,1}, Mao Jiang^{a,1}, Da Xia^b, Lichao He^b, Xin Lv^c, Xiaohua Liao^c, Jie Meng^{a,*}

^a Department of Pulmonary and Critical Care Medicine, The Third Xiangya Hospital of Central South University, Changsha, China

^b Department of Critical Care Medicine, The Fourth People's Hospital of Yiyang, Yiyang, China

^c Department of Nephrology, Xiangya Hospital of Central South University, Changsha, China

ARTICLE INFO

Keywords:

COVID-19
Familial cluster
Immunocompromised
Incubation period
Atypical infection
Shedding duration

ABSTRACT

Clusters of patients with novel coronavirus disease 2019 (COVID-19) have been successively reported globally. Studies show clear person-to-person transmission. The average incubation period is 2–14 days, and mostly 3–7 days. However, in some patients, this period may be longer. Here, we report a familial cluster of COVID-19 where a 47-year-old woman with long-term use of glucocorticoids did not develop any symptoms within the 14-day quarantine period but was confirmed with COVID-19 by tested positive of antibody on day 40 after she left Wuhan. Almost at the same time, her father and sister were diagnosed with COVID-19. The results suggest that the long-term use of glucocorticoids might cause atypical infections, a long incubation period, and extra transmission of COVID-19.

1. Introduction

In December 2019, a novel pneumonia resulting from SARS-CoV2, named coronavirus disease 2019 (COVID-19), emerged in Wuhan [1,2]. Due to the high viral contagiousness and transmission during the pre-symptomatic phase [3,4], COVID-19 progressively spread throughout China and has since become a global health issue [5]. In China, Wuhan city, the capital of Hubei province, became the center of a COVID-19 outbreak [6]. In an effort to prevent a COVID-19 epidemic, Wuhan and its surrounding cities in Hubei province were locked down on January 23rd. However, a tremendous number of patients who were still in their incubation period traveled across China before the lockdown date due to Chinese New Year, resulting in the widespread transmission of COVID-19. Hunan province is adjacent to Hubei province. By March 20th, 2020, a total of 1018 confirmed cases had been reported in Hunan, most of which showed familial clustering.

The average incubation period for COVID-19 is reported to be 2 to 14 days, and most patients show symptoms within 11.5 days [7,8]. To stop the spread of the disease, public health officials in Hunan placed those who may have been from Wuhan and exposed to COVID-19 under quarantine for 14 days. However, the incubation period may be longer in some patients. Here, we report on the last COVID-19 familial cluster

in Hunan province, which was hospitalized on February 28. The disease was not confirmed until 40 days after the index patient had returned from Wuhan.

2. Patients and methods

2.1. Case source

On February 28th, a new COVID-19 case was confirmed in the Fourth People's Hospital of Yiyang. In following the patient's epidemiological history, it emerged that this was a familial cluster. Afterward, we further collected the clinical data of the patient's family members, including epidemiological history, laboratory examinations, lung CTs, pathogen results, treatment course, and recovery. All the clinical data were collected from the Fourth People's Hospital of Yiyang, and all the epidemiological histories of the patients were gathered from the patients themselves; these data were further confirmed by the local Centers for Disease Control.

All the information used in this article was approved by the patients.

Abbreviations: COVID-19, coronavirus disease 2019; SARS-CoV2, severe acute respiratory syndrome – coronavirus 2; SLE, systemic lupus erythematosus; WBC, white blood cell; ESR, erythrocyte sedimentation rates

* Corresponding author at: Tongzipo Road 138, Yuelu District, Changsha, China.

E-mail address: mengjie@csu.edu.cn (J. Meng).

¹ These authors contribute equally to the manuscript.

<https://doi.org/10.1016/j.clim.2020.108413>

Received 26 March 2020; Received in revised form 5 April 2020; Accepted 6 April 2020

Available online 08 April 2020

1521-6616/ © 2020 Elsevier Inc. All rights reserved.

2.2. Quarantine standards taken in this study

The home quarantine involved in our article was completely implemented according to the announcement released by the National Health Commission of the People's Republic of China (http://www.gov.cn/zhengce/zhengceku/2020-02/05/content_5474688.htm, accessed 26 March 2020).

2.3. Detection of respiratory pathogens

Influenza A and B viruses and respiratory syncytial virus were tested by the Xpert Xpress Flu/RSV assay (GeneXpert System, Cepheid, Sunnyvale, CA, USA) according to the manufacturer's instructions [9]. The IgG/IgM of *Chlamydomphila pneumoniae* and *Mycoplasma pneumoniae* were also tested using the SeroMP kit (Savyon Diagnostics, Ashdod, Israel). The SARS-CoV2 nucleic acid test was conducted via real-time RT-PCR according to the protocol of the nucleic acid kit (Kangwei Century Biotechnology Company, China). The SARS-CoV2 antibody kit was used to test for specific IgM and IgG antibodies (Guangzhou Wonfo Biological Technology Co, Ltd., China) via colloidal gold immunochromatography.

3. Results

Five cases were detected in our research, all of whom were from the same family. We defined the case numbers from Case 1 to Case 5, and their epidemiological and clinical characteristics are presented in Fig. 1. Case 2 and Case 4 are the parents of Case 1, Case 3 is the younger sister of Case 1, and Case 5 is the husband of Case 3.

3.1. Case 1

Case 1 is a Wuhan-settled 47-year-old female. She has a more than 16-year history of systemic lupus erythematosus (SLE) and has been taking oral prednisone (7.5 mg/d) since her diagnosis. She had not taken hydroxychloroquine or other immunosuppressive drugs. On January 10th, 2020, she spent 1 h dancing and singing in a room and one of her partners was later diagnosed with COVID-19. In the

following 10 days, she had no contact with any confirmed or suspected patients. She returned to her parents' home in Yiyang on January 20th and after that never went out. Because of the severity of COVID-19, Hunan province carried out a 'level one response to major public health emergencies' on January 23. Therefore, Case 1 was placed under home quarantine and observation for 14 days. During the isolation period, she felt good and had no fever, cough or shortness of breath. Therefore, she was released from quarantine on February 6th. Just a day later, however, Case 1 began to have a mild cough, nasal congestion, and runny nose, but no fever. She paid little attention to her symptoms and did not seek further medical help. These symptoms improved 7 days later. On February 28th, she was admitted to hospital for screening because of her father's (Case 2) diagnosis of COVID-19. Her routine blood examination was abnormal, with a white blood cell (WBC) count of $2.98 \times 10^9/L$, hemoglobin concentration of 106 g/L, and platelet count of $73 \times 10^9/L$. Her erythrocyte sedimentation rate (ESR) was 33 mm/h, which was above normal. IL-6 was normal. The SARS-CoV2 nucleic acid test from nasopharyngeal swabs was negative, but her IgM and IgG antibodies were positive. *Mycoplasma pneumoniae* and *Chlamydia pneumoniae* antibodies were negative. Lung CT (Fig. 2A, B) showed multiple lesions in both lungs. These results supported the diagnosis of COVID-19. Hence, she was given antiviral treatment, including 0.2 g BID of Abidol orally and 5 million IU of interferon nebulization. Nasopharyngeal swab virus nucleic acid tests were performed again on February 29th and March 3rd, both of which were negative. On March 5th, her lung CT (Fig. 2C, D) worsened, and ground-glass opacity changes were found in the right upper lung. She was given extra piperacillin sodium tazobactam sodium (4.5 TID), and then glycyrrhizin (150 mg QD). Her CT showed improvements and she was discharged on March 9th.

3.2. Case 2

Case 2 is an 81-year-old male who has been living in Yiyang for many years. He has a history of prostate cancer and coronary heart disease. He had been living with his eldest daughter (Case 1) since she returned from Wuhan and had not gone out since then. He developed a paroxysmal dry cough and anorexia on February 21st. In the beginning,

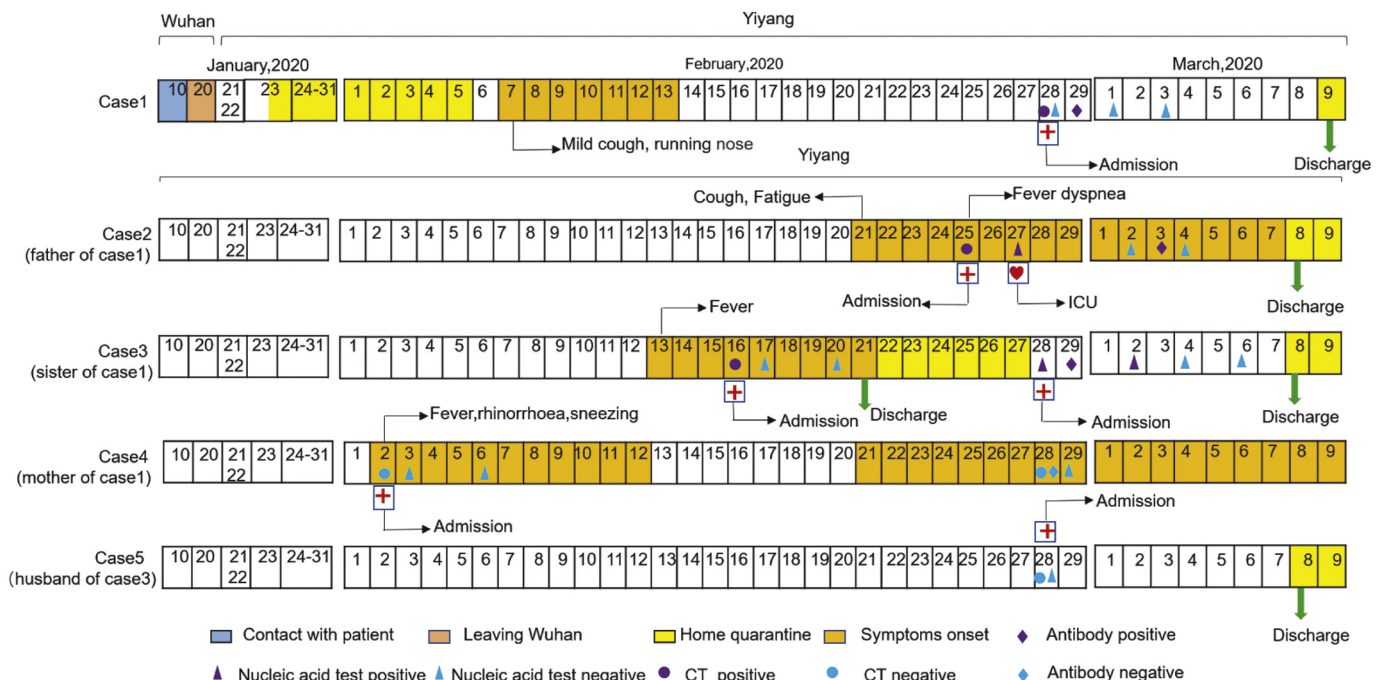


Fig. 1. The epidemiological and clinical characteristic of family cluster.

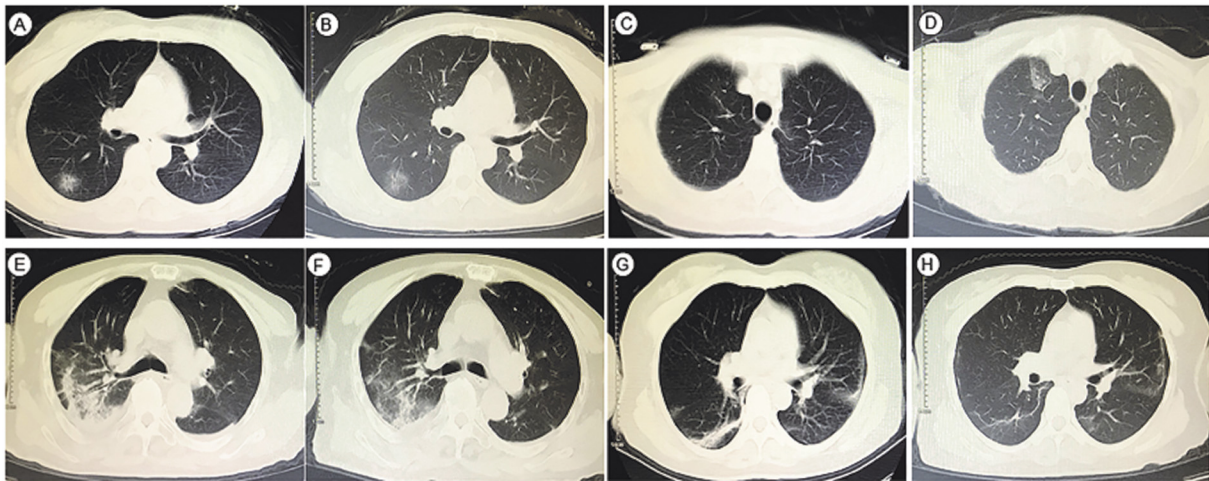


Fig. 2. Representative images of the thoracic CT scans. A, C) CT scans of Case 1 on February 28th show opacities in the right lower lobes. B, D) CT scans of Case 1 on March 5th show new ground glass opacity in the right upper lobe. E) CT scan of Case 2 on February 25th shows a mixed pattern of ground glass opacities and consolidation. F) CT scan of Case 2 on March 5th shows lesion resolution. G) CT scan of Case 3 on February 16th shows multiple patchy high density shadows of both lungs. H) CT scan of Case 3 on March 6th shows resolution.

he did not get treatment. On February 25th, the symptoms aggravated with a fever (38.0 °C) and shortness of breath. Influenza A and B viruses were negative. His chest CT (Fig. 2E) was abnormal with bilateral ground-glass opacities. His symptoms did not improve even after treatment with piperacillin-tazobactam (4.5 g Q48h), ambroxol, ribavirin (500 mg Q12h), and oseltamivir (75 mg BID). The SARS-CoV2 nucleic acid test was positive by both nasopharyngeal swabs and sputum on February 27th. His hemoglobin (83 g/L) and lymphocytes ($0.65 \times 10^9/L$) were below normal, and his D-dimer (5.46 mg/mL), C-reactive protein (134 mg/L), ESR (126 mm/h), IL-6 (7.6 pg/mL) were above normal. His arterial blood gas showed a PO₂ of 67 mmHg and a FiO₂ of 33%. Therefore, he was diagnosed with severe COVID-19 and admitted to the intensive care unit with support treatments including high fluids, oxygen, interferon, lopinavir-ritonavir and ribavirin for anti-viral therapy, linezolid, meropenem and fluconazole for anti-inflammation, and albumin, gamma globulin, steroids (80 mg/d) and recovery plasma (200 mL* 2) to improve his immune system. His virus nucleic acid tests were retested on March 2nd and March 4th, with both showing negative. On March 3rd, his IgM and IgG specific antibodies were positive. Repeat blood gas on March 5th showed a PO₂ of 114 mmHg and a FiO₂ of 33%. His lung CT (Fig. 2F) showed that his inflammation lesions were absorbed and ground-glass opacities were improved.

3.3. Case 3

Case 3 is a 44-year-old female from Yiyang. She also had close contact with her elder sister (Case 1). She developed a fever (37.8 °C) and inappetence on February 13th. Three days later, she was taken to a hospital. Laboratory examination showed a WBC of $2.88 \times 10^9/L$, C-reactive protein of 17.06 mg/L, and fibrinogen of 4.27 g/L. Influenza A and B were negative. Lung CT (Fig. 2G) showed multiple patchy high-density shadows on both lungs. On February 17th and February 20th, the nasopharyngeal swab was negative for SARS-CoV2. After treatment, the symptoms disappeared. Hence, she was discharged on February 21st and placed under home quarantine. Since her father (Case 2) was diagnosed with COVID-19 on February 28th, she was admitted to the hospital again for further screening. This time, her SARS-CoV2 nucleic acids and specific IgG and IgM antibodies were positive. The ESR was 55.6 mm/h. Antiviral therapy was given with interferon and lopinavir-ritonavir. On March 2nd, her repeat viral nucleic acid test was still positive. The nasopharyngeal swab was negative twice, respectively on March 4th and March 6th, with simultaneously improved lung CT

(Fig. 2H).

3.4. Case 4 and Case 5

Case 4 and Case 5 were the other two family members but were excluded from COVID-19. Remarkably, Case 4, who developed fever, was diagnosed with malignant lymphoma according to the result of her bone marrow puncture.

4. Discussion

The ongoing outbreak of COVID-19, starting in December 2019, has quickly become a sweeping and unprecedented global challenge. Because COVID-19 can spread from person to person [10,11], a major challenge in controlling the disease is recognizing and quarantining potential infectious sources as soon as possible [12].

As Li reported, the median incubation period is 4–5.2 days and the 95th percentile of the distribution is 12.5 days [13]. Unfortunately, COVID-19 patients can be infective before the disease onset and maintain infective ability during the convalescent phase [3,4,14]. According to Cao's report [15], the shortest observed duration of viral shedding was 8 days, whereas the longest was 37 days. However, to date, no article has reported what kind of patients have a longer viral shedding time. In the family we report here, the index patient, Case 1, was from Wuhan and had contact with COVID-19 patients before she returned to Yiyang city. The other 4 family members were from Yiyang and had never left Yiyang, nor did they have contact with any other COVID-19 patients. It is most likely that Case 1 was the infective source in this family. By further examining their epidemiological data, we find that the incubation period of COVID-19 and the shedding duration of SARS-CoV2 might be extremely long in this case. The index patient did not develop atypical symptoms (including a mild cough and a runny nose) until 28 days after she had returned from Wuhan. Remarkably, Case 1 was immunocompromised due to her long-term use of oral prednisone, which might explain why she did not develop typical symptoms at first and why she had a longer duration of viral shedding.

In summary, it is important to recognize potential patients who might have no or only mild symptoms. Therefore, we highly recommend that all people with an exposure history be strictly quarantined, and for immunocompromised people with long-term use of glucocorticoids, this time should not be limited to 14 days.

Funding

This work was supported by the Emergency Project of Prevention and Control for COVID-19 of Central South University (Grant 16026000 to Jie Meng), and COVID-19 Project of Changsha Science and Technology Bureau (Grant 38065 to Jie Meng).

Declaration of Competing Interest

We declare no competing interests.

Acknowledgments

We thank Huanxing Sun (Yale University School of Medicine, New Haven, USA) and Lingzhong Meng (Yale University School of Medicine, New haven, USA) for reviewing and checking the wordings of the manuscript. All authors also gratefully acknowledge relevant medical workers and local Centers for Disease Control.

References

- [1] Na Zhu, Zhang Dingyu, Wenling Wang, et al., A novel coronavirus from patients with pneumonia in China, 2019, *N. Engl. J. Med.* 382 (2020) 727–733.
- [2] Yuntao Wu, Ho Wenzhe, Huang Yaowei, et al., SARS-CoV-2 is an appropriate name for the new coronavirus, *Lancet* 395 (10228) (2020) 949–950.
- [3] Zhiliang Hu, Song Ci, Xu Chuanjun, et al., Clinical characteristics of 24 asymptomatic infections with COVID-19 screened among close contacts in Nanjing, China, *Sci. China Life Sci.* (2020), <https://doi.org/10.1007/s11427-020-1661-4>.
- [4] Huang Rui, Xia Juan, Chen Yuxin, et al., A family cluster of SARS-CoV-2 infection involving 11 patients in Nanjing, China, *Lancet Infect. Dis.* (2020), [https://doi.org/10.1016/S1473-3099\(20\)30147-X](https://doi.org/10.1016/S1473-3099(20)30147-X).
- [5] B. Jernigan Daniel, CDC COVID-19 response team, update: public health response to the Coronavirus disease 2019 outbreak - United States, February 24, 2020, *MMWR Morb. Mortal. Wkly Rep.* 69 (2020) 216–219.
- [6] Yongshi Yang, Peng Fujun, Runsheng Wang, et al., The deadly coronaviruses: The 2003 SARS pandemic and the 2020 novel coronavirus epidemic in China, *J. Autoimmun.* (2020), <https://doi.org/10.1016/j.jaut.2020.102434>.
- [7] Ping Yu, Zhu Jiang, Zhang Zhengdong, et al., A familial cluster of infection associated with the 2019 novel coronavirus indicating potential person-to-person transmission during the incubation period, *J. Infect. Dis.* (2020), <https://doi.org/10.1093/infdis/jiaa077>.
- [8] A. Lauer Stephen, H. Grantz Kyra, Bi Qifang, et al., The Incubation Period of Coronavirus Disease 2019 (COVID-19) From Publicly Reported Confirmed Cases: Estimation and Application, *Ann. Intern. Med.* (2020), <https://doi.org/10.7326/M20-0504>.
- [9] To KKW, C.C.Y. Yip, C.Y.W. Lai, et al., Saliva as a diagnostic specimen for testing respiratory virus by a point-of-care molecular assay: a diagnostic validity study, *Clin. Microbiol. Infect.* 25 (2019) 372–378.
- [10] First known person-to-person transmission of severe acute respiratory syndrome coronavirus 2 (SARS-CoV-2) in the USA.
- [11] Chan Jasper Fuk-Woo, Yuan Shuofeng, Kok Kin-Hang, et al., A familial cluster of pneumonia associated with the 2019 novel coronavirus indicating person-to-person transmission: a study of a family cluster, *Lancet* 395 (2020) 514–523.
- [12] Li Ruiyun, Pei Sen, Chen Bin, et al., Substantial undocumented infection facilitates the rapid dissemination of novel coronavirus (SARS-CoV2), *Science* (2020), <https://doi.org/10.1126/science.abb3221>.
- [13] Li Qun, Guan Xuhua, Peng Wu, et al., Early transmission dynamics in Wuhan, China, of novel coronavirus-infected pneumonia, *N. Engl. J. Med.* 382 (13) (2020) 1199–1207.
- [14] Rothe Camilla, Schunk Mirjam, Sothmann Peter, et al., Transmission of 2019-nCoV infection from an asymptomatic contact in Germany, *N. Engl. J. Med.* 382 (2020) 970–971.
- [15] Zhou Fei, Ting Yu, Du Ronghui, et al., Clinical course and risk factors for mortality of adult inpatients with COVID-19 in Wuhan, China: a retrospective cohort study, *Lancet* 395 (10229) (2020) 1054–1062.