



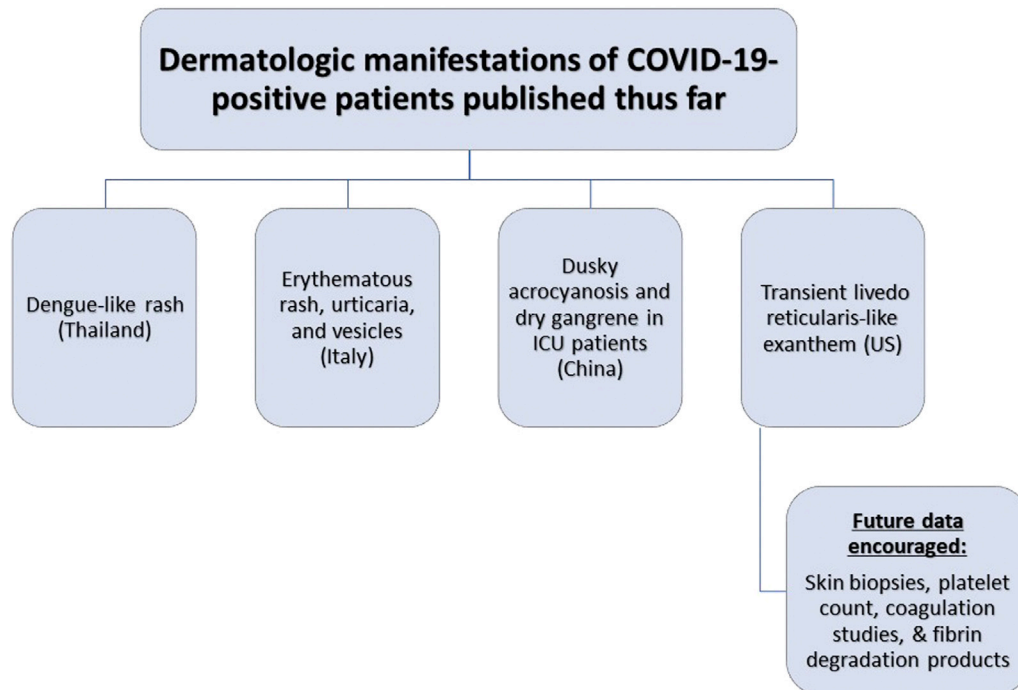
Since January 2020 Elsevier has created a COVID-19 resource centre with free information in English and Mandarin on the novel coronavirus COVID-19. The COVID-19 resource centre is hosted on Elsevier Connect, the company's public news and information website.

Elsevier hereby grants permission to make all its COVID-19-related research that is available on the COVID-19 resource centre - including this research content - immediately available in PubMed Central and other publicly funded repositories, such as the WHO COVID database with rights for unrestricted research re-use and analyses in any form or by any means with acknowledgement of the original source. These permissions are granted for free by Elsevier for as long as the COVID-19 resource centre remains active.

INFOGRAPHICS

A dermatologic manifestation of COVID-19: Transient livedo reticularis

Iviensan F. Manalo, MD,^a Molly K. Smith, MD,^b Justin Cheeley, MD,^{a,c} and Randy Jacobs, MD^d
Atlanta, Georgia; Norfolk, Virginia; and Riverside, California



Infographic 1. Dermatologic manifestations of COVID-19-positive patients published thus far. Supplemental Material available via Mendeley at <https://doi.org/10.17632/kgb87k7863.1>.

From the Department of Dermatology, Emory University School of Medicine, Atlanta, Georgia^a; Pariser Dermatology Specialists, Norfolk, Virginia^b; Department of Medicine, Emory University School of Medicine, Atlanta, Georgia^c; and University of California Riverside School of Medicine, Riverside, California.^d

Funding sources: None.

Conflicts of interest: None disclosed.

IRB approval status: Not applicable.

Reprint requests: Iviensan Manalo, MD, Department of Dermatology, Emory University School of Medicine, 1525 Clifton Rd, Ste 100, Atlanta, GA 30329. E-mail: ivie.manalo@gmail.com.

J Am Acad Dermatol 2020;■■■:■.

0190-9622/\$36.00

© 2020 by the American Academy of Dermatology, Inc.

<https://doi.org/10.1016/j.jaad.2020.04.018>