




Since January 2020 Elsevier has created a COVID-19 resource centre with free information in English and Mandarin on the novel coronavirus COVID-19. The COVID-19 resource centre is hosted on Elsevier Connect, the company's public news and information website.

Elsevier hereby grants permission to make all its COVID-19-related research that is available on the COVID-19 resource centre - including this research content - immediately available in PubMed Central and other publicly funded repositories, such as the WHO COVID database with rights for unrestricted research re-use and analyses in any form or by any means with acknowledgement of the original source. These permissions are granted for free by Elsevier for as long as the COVID-19 resource centre remains active.



Review article

Hepatic and gastrointestinal involvement in coronavirus disease 2019 (COVID-19): What do we know till now?

Sherief Musa

Endemic Hepatogastroenterology Department, Faculty of Medicine, Cairo University, Cairo, Egypt



ARTICLE INFO

Keywords:
SARS-CoV-2
COVID-19
Liver
Gastrointestinal tract
Endoscopy

ABSTRACT

Since December 2019, the severe acute respiratory syndrome coronavirus 2 (SARS-CoV-2), the causative pathogen of coronavirus disease 2019 (COVID-19), has posed a serious threat to global health and is currently causing a major pandemic. While patients typically present with fever and a respiratory illness, mounting evidence indicates that patients might also report extra-pulmonary manifestations, including those affecting the liver and gastrointestinal tract. This involvement may have important implications to the disease management, transmission, and prognosis, especially in patients with pre-existing hepatic or digestive co-morbidities.

In this review, the characteristics and possible explanations of hepatic and gastrointestinal involvement caused by SARS-CoV-2 infection are summarized, adding to our knowledge of the spectrum of COVID-19. In addition, preventive measures implemented in endoscopy departments to prevent further dissemination of SARS-CoV-2 infection are proposed.

© 2020 Pan-Arab Association of Gastroenterology. Published by Elsevier B.V. All rights reserved.

The end of 2019 was marked by emergence of an outbreak caused by a novel coronavirus, severe acute respiratory syndrome coronavirus 2 (SARS-CoV-2), initially reported in Wuhan, China [1]. More than 200 000 laboratory confirmed cases and nearly 10 000 deaths in over 100 countries have been reported to date [2], leading the World Health Organization in March 11, 2020 to characterize the infection, subsequently named coronavirus disease 2019 (COVID-19), as a pandemic [3]. The spectrum of symptomatic COVID-19 ranges from mild respiratory tract infection to severe pneumonia that may progress to acute respiratory distress syndrome or multi-organ dysfunction [4]. It is well established that fever along with respiratory symptoms such as cough and dyspnoea represent the common symptoms of COVID-19 similar to the diseases caused by the other two highly pathogenic coronaviruses: severe acute respiratory syndrome (SARS) in 2003 and Middle East respiratory syndrome (MERS) in 2012 [5]. There is uncertainty about extra-pulmonary manifestations of COVID-19, including those affecting the liver and gastrointestinal tract. This review aims to provide insight into characteristics, possible mechanisms and implications of hepatic and gastrointestinal involvement caused by SARS-CoV-2 infection, adding to our knowledge of the spectrum of COVID-19.

COVID-19 and the liver

Liver involvement has been reported in patients infected with SARS-CoV [6] and MERS-CoV [7]. Likewise, published case studies reporting clinical features of patients with COVID-19 have shown that they may develop different degrees of liver dysfunction (summarized in Table 1). In these studies, the incidence of liver injury ranged from 14.8% to 78%, mainly presenting with abnormal levels of alanine aminotransferase (ALT) and aspartate aminotransferase (AST) accompanied by slightly elevated bilirubin levels [8–19]. A deeper look at available data shows higher rates of abnormal levels in severe COVID-19, as high as 78% in one study [18].

Currently, the underlying mechanisms for hepatic injury in patients with COVID-19 are still unclear. Liver damage might be directly caused by virus-induced cytopathic effects. SARS-CoV-2 binds to the angiotensin-converting enzyme 2 (ACE2) receptor to enter its target cells [20]. Data from two independent cohorts revealed significant enrichment of ACE2 expression in cholangiocytes (59.7% of cells) compared to hepatocytes (2.6% of cells) suggesting that SARS-CoV-2 might directly bind to ACE2-positive cholangiocytes to dysregulate liver function [21]. Although ACE2 is highly expressed in bile duct cells, recent works suggest that gamma-glutamyl transferase (GGT) was elevated in 54% of COVID-19 patients, whereas only 1.8% of patients (1/56) had elevated alkaline phosphatase level [22]. Elsewhere, pathological

E-mail address: sheriefmusa@cu.edu.eg

Table 1
Characteristics of liver biochemical profile in published COVID-19 case studies.

	Patients with COVID-19	Patients with abnormal biochemical liver profile	Patients with pre-existing liver co-morbidities
Guan et al. [8]	1099	Abnormal ALT, 158/741 (21.3%): - 19.8% in non-severe COVID-19 - 28.1% in severe COVID-19 Abnormal AST, 168/757 (22.2%): - 18.2% in non-severe COVID-19 - 39.4% in severe COVID-19 Abnormal total bilirubin 76/722 (10.5%) - 9.9% in non-severe COVID-19 - 13.3% in severe COVID-19	23 (2.1%)
Cai et al. [9]	298	44 (14.8%) 9.6% in non-severe COVID-19 36.2% in severe COVID-19	8 (2.7%)
Fan et al. [10]	148	75 (50.7%)- Abnormal ALT (18.2%)- Abnormal AST (21.6%)- Abnormal total bilirubin (6.1%)	6 (8%)
Wang et al [11]	138	Mild elevation of ALT and AST	4 (2.9%)
Chen et al [12]	99	43 (43%) - Abnormal ALT 28% - Abnormal AST 35% - Abnormal total bilirubin 18% - Abnormal albumin 98%	NA
Lu et al. [13]	85	33 (38.8%)	6 (7%)
Shi et al. [14]	81	43 (53%)	7 (9%)
Xu et al. [15]	62	10 (16%)	7 (11%)
Yang et al. [16]	52	15 (29%)	NA
Huang et al. [17]	41	15(31%)	1(2%)
Zhang et al. [18]	82, deaths	64 (78%) - Abnormal ALT 30.6% - Abnormal AST 61.1% - Abnormal total bilirubin 30.6%	2(2.4%)
Huang et al. [19]	36, non-survivors	- Abnormal ALT 13% - Abnormal AST 58% - Abnormal total bilirubin 12.9%	NA

Abbreviations: SARS-Cov-2, severe acute respiratory syndrome coronavirus 2; ALT, alanine transaminase; AST, aspartate aminotransferase.

analysis of hepatic tissue from a patient who died from COVID-19 did not find viral inclusions in the liver [23].

In addition, immune-mediated inflammation might contribute to liver injury in patients with COVID-19 who are critically ill [22]. Previous studies have shown that inflammatory cytokine storm is associated with adverse outcomes of SARS-CoV [24] or MERS-CoV infection [25]. Inflammatory cytokine storm is an overactive inflammatory response, which leads to persistent activation of lymphocytes and macrophages that secrete huge amount of inflammatory cytokines [26]. Lymphocytes are important for inhibiting overactive innate immune responses during viral infection [27]. Thus, the typical lymphopenia during SARS-CoV-2 infection may result in increases in interleukin-6 (IL-6), IL-10, IL-2 and IFN- γ levels and aggravated inflammatory responses, leading not only to pulmonary injury, but also the injury of non-pulmonary organs including the liver [28]. A study of the risk factors involved with hepatic injury in patients with COVID-19, found that lymphopenia and CRP level were independently associated with liver injury, suggesting that inflammatory cytokine storm might be the major mechanism [29].

Another possible contributing factor may be the high levels of positive end expiratory pressure that can cause hepatic congestion by increasing right atrial pressure and impeding venous return. However, published data suggest that admitted patients with COVID-19 have liver abnormalities without mechanical ventilation. Furthermore, the distribution of aminotransferase levels among patients with COVID-19 does not support hypoxic hepatitis being common [30]. Importantly, drug-induced liver injury during COVID-19 treatment should be carefully investigated. It might be caused by antiviral medications (lopinavir/ritonavir), antipyretics (acetaminophen), antibiotics (macrolides, quinolones) or steroids [31]. In a paper describing the first 12 patients with COVID-19 in the United States (U.S.), the three hospitalized patients, who

received remdesivir at the time of clinical worsening, reported elevated liver enzymes [32].

COVID-19 and pre-existing liver disease

Given the high burden of chronic liver disease worldwide, interactions between pre-existing liver disease and COVID-19 need to be further investigated. Preliminary data indicate 2–11% of patients with COVID-19 had liver comorbidities [22]. However, the exact cause of pre-existing liver conditions has not been outlined in the published case studies (Table 1).

In a study of 1099 patients with laboratory confirmed COVID-19, 23 (2.1%) patients had hepatitis B infection. Severe cases were more likely to have hepatitis B infection (2.4% vs 0.6%) than non-severe cases [8]. SARS patients with HBV/HCV infection were more prone to develop severe hepatitis, probably due to enhanced viral replication during SARS-CoV infection [33]. Individuals at high risk for severe COVID-19 are typically of older age and/or present with comorbid conditions such as diabetes, cardiovascular disease, and hypertension, a similar profile to those at increased risk for non-alcoholic fatty liver disease, making them more susceptible to liver injury. In patients with COVID-19 with autoimmune hepatitis, the effects of administration of glucocorticoids on disease prognosis is unclear. Given the expression of the ACE2 receptor in cholangiocytes, whether infection with SARS-CoV-2 aggravates cholestasis in patients with primary biliary cholangitis, needs to be studied [22].

Moreover, patients with liver cirrhosis might be more susceptible to infections because of their systemic immunocompromised status [34], thus, preventing infection with SARS-CoV-2 is of utmost importance. In a study of 111 patients with decompensated cirrhosis in Wuhan, none of the participants had clinical symptoms suggestive of SARS-CoV-2 infection, when certain precautionary

approach was maintained, in contrast to an incidence of 17% of COVID-19 among a comparative group of 101 decompensated cirrhotics at other hospitals where these measures had not been implemented [35]. Finally, liver transplantation might involve a risk of transmission of viral infection from donor to recipient, as shown in the previous SARS outbreak [36]. Michaels and colleagues recently described possible risks associated with transplant in COVID-19 positive recipients [37]. In Italy, where the COVID-19 outbreak is rapidly spreading, the Italian Transplant Authority recommended nasopharyngeal swab or bronchoalveolar lavage to identify COVID-19 before donation, with consequent exclusion of positive donors [38].

COVID-19 and the gastrointestinal tract

Since SARS-CoV-2 RNA was first detected in a stool specimen of the first reported COVID-19 patient in the U.S., much attention has been paid to gastrointestinal tract infection by SARS-CoV-2 [39]. Gastrointestinal involvement is well known in coronavirus infections of animals and humans [40]. Previous studies have revealed that 10.6% of patients with SARS and up to 30% of patients with MERS had diarrhea [41].

Similarly, data from early reports of the current pandemic suggest that concurrent gastrointestinal symptoms are not uncommon in patients with COVID-19 [42]. In one of these studies, nausea or vomiting, or both, and diarrhoea were reported in 55 (5.6%) and 42 (3.8%) patients [8]. In another cross-sectional study, enrolling 204 patients with confirmed COVID-19 from 3 hospitals in Hubei province, 99 patients (48.5%) presented with digestive symptoms as the chief complaint, including 7 cases in which there were no respiratory symptoms [40]. This should alert gastroenterologists to raise their index of suspicion when at-risk patients present with digestive symptoms rather than waiting for respiratory symptoms to emerge. This may help with earlier identification of COVID-19 with earlier treatment and isolation [42].

A recent study by Wei et al. attempted to delineate differences between COVID-19 patients with diarrhoea (26/84) and those without. Despite finding no difference in most of the laboratory and radiologic findings, they noticed that COVID-19 patients with diarrhoea suffered headache, myalgia or fatigue, cough, sputum production, nausea, vomiting more frequently than those patients without diarrhoea, but seldomly suffered abdominal pain, abdominal distension and tenesmus [43].

Patients without digestive symptoms were more likely to be cured and discharged than patients with digestive symptoms (60% vs. 34.3%). This could be due to either viral replication in the gastrointestinal tract causing more severe disease or that patients who do not initially have typical respiratory symptoms present with later stages of disease [42].

There are many hypotheses why COVID-19 appears to cause digestive symptoms, but, the exact molecular mechanism needs to be further investigated. Firstly, interaction between SARS-CoV-2 and ACE2 might result in diarrhoea. A recent bioinformatics analysis revealed that ACE2 was not only highly expressed in alveolar type II (AT2) cells in the lung, but also in the glandular cells of gastric and duodenal epithelia [44]. Similar findings were found in the study by Liang et al. [45], ACE2 was highly expressed in proximal and distal enterocytes, directly exposed to food and foreign pathogens. The ACE2-expressing enterocytes are invaded by SARS-CoV-2, leading to malabsorption, unbalanced intestinal secretion and activated enteric nervous system, resulting in diarrhoea finally [44]. Secondly, SARS-CoV-2 indirectly damages the digestive system through a chain of inflammatory responses [42]. Another possible factor causing diarrhoea in COVID-19 patients might be antibiotic associated diarrhea [43]. Finally, changes in the composition and function of

digestive tract flora mutually affect the respiratory tract through immune regulation, the so-called “gut-lung axis” [46].

Autopsy studies are needed to understand the digestive system involvement of COVID-19; however, to date, there has been only one autopsy report for an 85-year-old man with COVID-19, which showed segmental dilatation and stenosis in the small intestine [47]. Whether this finding is secondary to COVID-19 is unknown [48].

All these findings and hypotheses could have a clear impact regarding transmission precautions, especially in hospitalized patients. Considering the evidence of faecal excretion for both SARS-CoV and MERS-CoV [49], it is possible that the digestive system may serve as an alternative route of SARS-CoV-2 infection. It has been reported that the stool from confirmed cases tested positive by RT-PCR for SARS-CoV-2 [39]. In terms of the fact that most of the patients in the initial outbreak reported a link to a wild animal market, this observation raises questions about whether this virus was transmitted via contaminated food at the small intestine [45]. Another issue of potential significance, is the extended duration of viral shedding in faeces. In one study, it was observed that for over half of patients, faecal samples remained positive for SARS-CoV-2 RNA for a mean of 11.2 days after viral clearance in respiratory tract samples [50]. According to current guidance, the decision to discharge hospitalized COVID-19 patients is based on negative results of RT-PCR testing for SARS-CoV-2 from at least two sequential respiratory tract specimens collected ≥ 24 h apart [51]. Therefore, routine stool sample testing with RT-PCR could be added and transmission-based precautions should be continued if faecal samples test positive [50].

COVID-19 and pre-existing digestive diseases

In general, presence of co-morbidities is associated with poorer outcomes in patients with COVID-19. This may have implications for the management of patients with pre-existing digestive diseases [52]. Patients with cancer are more susceptible to infection, however, whether patients with gastrointestinal cancers are more likely to be infected with SARS-CoV-2 than healthy individuals remains unknown [48]. In a nationwide analysis from China, 18 (1%) of 1590 COVID-19 cases had a history of cancer. Among these 18 cases, three had a history of colorectal cancer. Patients with COVID-19 and cancer had a higher risk of severe events [53]. Likewise, patients with inflammatory bowel disease (IBD) using biologics and immunosuppressive agents are at increased risk for more frequent and severe infections and could be more susceptible to SARS-CoV-2 infection [48]. Fortunately, with early precautions for COVID-19 prevention and control, not a single patient of the 318 patients (204 with ulcerative colitis and 114 with Crohn's disease) in the IBD registry in Wuhan, has been reported to be infected with SARS-CoV-2 [54]. These precautions included recommendations on the use of immunosuppressive agents and biologics, diet, and intentional postponement of elective surgery and endoscopy, as well as personal protection provisions [55]. In regard to recurrent *Clostridioides difficile* infection, experts in faecal microbiota transplantation believe that screening of stool donors is needed, as the risk of transmitting SARS-CoV-2 might be higher than that in other tissue transplants [56].

COVID-19 in the endoscopy unit

Worldwide, as millions of people are instructed to stay home to minimize SARS-CoV-2 transmission, health-care workers are at high risk from COVID-19. Figures from China's National Health Commission show that more than 3300 health-care workers have been infected as of early March [57]. Despite being not directly

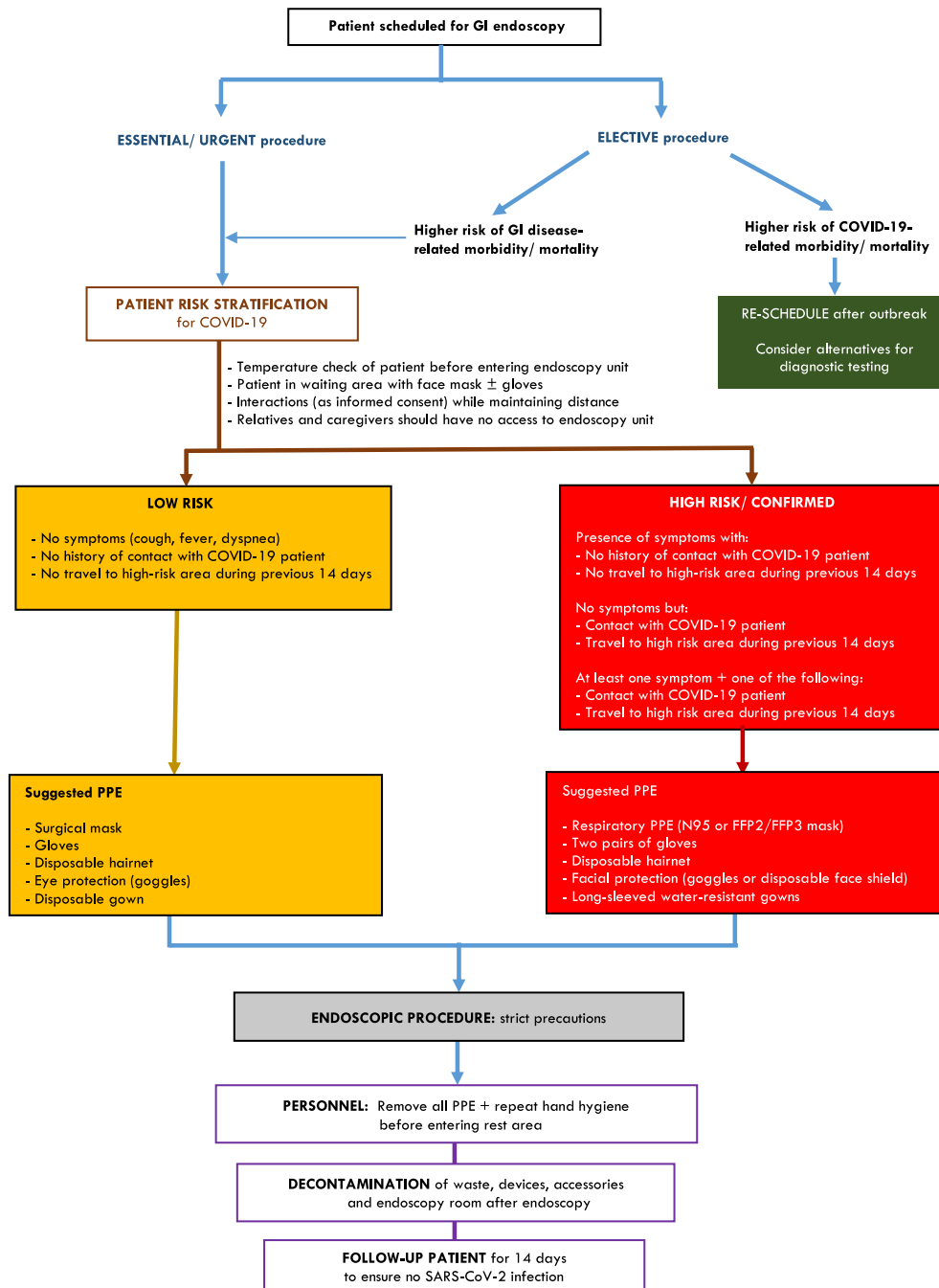


Fig. 1. Suggested workflow in GI endoscopy units during SARS-CoV-2 outbreak.

involved in management of COVID-19 patients, personnel working in endoscopy units are still at increased risk from inhalation of airborne droplets, conjunctival contact, and touch contamination [58]. Human-to-human transmission occurs primarily via infected droplets [59]. Airway suctioning, and other cough-inducing procedures pose an increased risk of transmission of SARS-CoV-2 [58]. It must be noted that the risk of exposure is not limited to upper endoscopy considering the potential transmission through faecal shedding [60].

All endoscopy facilities should develop standard operating measures for COVID-19 prevention and control in conjunction with infection control team members, and share these widely among staff members [61]. Based on prior experience from SARS and our current understanding of epidemiological characteristics of

COVID-19, the following steps should be implemented in endoscopy units:

- 1. Reduction of non-essential exposure to SARS-CoV-2:** It is recommended to limit endoscopy during the current outbreak to emergency procedures to treat patients with conditions such as acute gastrointestinal bleeding, foreign bodies in the gastrointestinal tract and acute cholangitis secondary to biliary obstruction [62].
- 2. Risk assessment and stratification of patients prior to any endoscopic procedure:** A high index of suspicion to diagnose SARS-CoV-2 infection, is crucial for prevention of transmission. Screening of patients for COVID-19 should be based on case definitions established by WHO and local health authorities [63].

The assessment must include history of fever, respiratory symptoms, or diarrhea, history of contact with a suspected or confirmed case of COVID-19 and any recent travel to a high-risk area [61].

3. **Negative-pressure room:** Whenever possible, endoscopy should be performed in an isolated room with negative pressure. If not available, endoscopy should be performed in a dedicated room with adequate ventilation [64].
4. **Staff protection:** The minimal composition of personal protective equipment (PPE) for personnel in endoscopy units should include gloves, hairnet, protective eyewear (goggles or face shield), waterproof gowns, and respiratory protective equipment, modified on the basis of risk stratification [61]. The surgical facial mask is effective in blocking splashes and large-particle droplets, whereas, filtering facepiece (FFP) respirator class 2 or 3 (FFP2/FFP3) achieves efficient filtration of airborne particles (up to 0.3 µm) [65]. In addition to PPE, health care workers must be educated the principles of contact and airborne precautions for both suspect and probable COVID-19 patients [64].
5. **Reprocessing of endoscopes and endoscopic accessories:** Enveloped viruses such as SARS-CoV-2 can be inactivated by disinfectants having virucidal activity [67]. Whereas high-level disinfection is recommended for endoscopes, and other “semi-critical” instruments, sterilization is recommended for “critical” instruments, including biopsy forceps, polypectomy snares and papillotomes. Disposable accessories are an alternative to sterilization of reusable devices [68].
6. **Decontamination of endoscopy rooms:** This process should include cleaning all surfaces in the procedure room to remove all soil and biofilm, followed by proper disinfection [61]. Chlorine-containing detergents are recommended for floor cleaning every day [67].

To prevent SARS-CoV-2 transmission in endoscopy units during the current outbreak, a workflow is proposed (Fig. 1) in accordance with recommendations of endoscopy societies [61–66].

References

- [1] Del Rio C, Malani PN. 2019 novel coronavirus-important information for clinicians. *JAMA* 2020.
- [2] WHO. Coronavirus disease 2019 (COVID-19) Situation Report – 60. 20 March 2020. https://www.who.int/docs/default-source/coronavirus/situation-reports/20200320-sitrep-60-covid-19.pdf?sfvrsn=8894045a_2
- [3] WHO Director-General’s opening remarks at the media briefing on COVID-19 – 11 March 2020. <https://www.who.int/dg/speeches/detail/who-director-general-s-opening-remarks-at-the-media-briefing-on-covid-19--11-march-2020>
- [4] Wu Z, McGoogan JM. Characteristics of and important lessons from the Coronavirus Disease 2019 (COVID-19) outbreak in China: summary of a Report of 72314 cases from the Chinese Center for Disease Control and Prevention. *JAMA* 2020.
- [5] Su S, Wong G, Shi W, et al. Epidemiology, genetic recombination, and pathogenesis of coronaviruses. *Trends Microbiol* 2016;24(6):490–502.
- [6] Chau TN, Lee KC, Yao H, et al. SARS-associated viral hepatitis caused by a novel coronavirus: report of three cases. *Hepatology* 2004;39(2):302–10. <https://doi.org/10.1002/hep.20111>.
- [7] Alsaad KO, Hajeer AH, Al Balwi M, et al. Histopathology of Middle East respiratory syndrome coronavirus (MERS-CoV) infection—clinicopathological and ultrastructural study. *Histopathology* 2018;72:516–24.
- [8] Guan W, Ni Z, Hu Y, et al. Clinical characteristics of novel coronavirus infection in China. *NEJM* 2019. <https://doi.org/10.1056/NEJMoa2002032>.
- [9] Cai Q, Huang D, Ou P et al. COVID-19 in a Designated Infectious Diseases Hospital Outside Hubei Province, China [J]. *medRxiv* 2020.02.17.20024018; in press. <https://doi.org/10.1101/2020.02.17.20024018>.
- [10] Fan Z, Chen L, Li Jun et al. Clinical Features of COVID-19-Related Liver Damage. *medRxiv* 2020.02.26.20026971; in press. Available from: <https://doi.org/10.1101/2020.02.26.20026971>.
- [11] Wang D, Hu B, Hu C, et al. Clinical characteristics of 138 hospitalised patients with 2019 novel coronavirus-infected pneumonia in Wuhan, China. *JAMA* 2020; published online Feb 7. DOI:10.1001/jama.2020.1585.
- [12] Chen N, Zhou M, Dong X, et al. Epidemiological and clinical characteristics of 99 cases of 2019 novel coronavirus pneumonia in Wuhan, China: a descriptive study. *Lancet* 2020;395:507–13.
- [13] Lu Li, Shuang Li, Manman Xu, et al. Risk factors related to hepatic injury in patients with corona virus disease 2019. *medRxiv preprint* doi: <https://doi.org/10.1101/2020.02.28.20028514>.
- [14] Shi Heshui, Han Xiaoyu, Jiang Nanchuan, Cao Yukun, Alwalid Osamah, Gu Jin, Fan Yanqing, Zheng Chuansheng. Radiological findings from 81 patients with COVID-19 pneumonia in Wuhan, China: a descriptive study. *Lancet Infect Dis* 2020. [https://doi.org/10.1016/S1473-3099\(20\)30086-4](https://doi.org/10.1016/S1473-3099(20)30086-4).
- [15] Xu X-W, Wu X-X, Jiang X-G, et al. Clinical findings in a group of patients infected with the 2019 novel coronavirus (SARS-Cov-2) outside of Wuhan, China: retrospective case series. *BMJ* 2020; published online Feb 19. DOI:10.1136/bmj.m606.
- [16] Yang X, Yu Y, Xu J, et al. Clinical course and outcomes of critically ill patients with SARS-CoV-2 pneumonia in Wuhan, China: a single-centered, retrospective, observational study. *Lancet Respir Med* 2020. [https://doi.org/10.1016/S2213-2600\(20\)30079-5](https://doi.org/10.1016/S2213-2600(20)30079-5).
- [17] Huang C, Wang Y, Li X, et al. Clinical features of patients infected with 2019 novel coronavirus in Wuhan, China. *Lancet* 2020;395:497–506.
- [18] Zhang B, Zhou X, Qiu Y et al. Clinical characteristics of 82 death cases with COVID-19[J]. *medRxiv* 2020.02.26.20028191; in press. <https://doi.org/10.1101/2020.02.26.20028191>.
- [19] Huang Y, Zhou H, Yang R et al. Clinical characteristics of 36 non-survivors with COVID-19 in Wuhan, China. *medRxiv* 2020.02.27.20029009; in press. <https://doi.org/10.1101/2020.02.27.20029009>.
- [20] Hoffmann M, Kleine-Weber H, Krüger N, et al. The novel coronavirus 2019 (2019-nCoV) uses the SARS-1 coronavirus receptor ACE2 and the cellular protease TMPRSS2 for entry into target cells. *bioRxiv* 2020.01.31.929042; in press. <https://doi.org/10.1101/2020.01.31.929042>.
- [21] Chai X, Hu L, Zhang Y, et al. Specific ACE2 expression in cholangiocytes may cause liver damage after 2019-nCoV infection. *bioRxiv* 2020; published online Feb 4. <https://doi.org/10.1101/2020.02.03.931766>.
- [22] Zhang Chao, Shi Lei, Wang Fu-Sheng. Liver injury in COVID-19: management and challenges. *Lancet Gastroenterol Hepatol* 2020. [https://doi.org/10.1016/S2468-1253\(20\)30057-1](https://doi.org/10.1016/S2468-1253(20)30057-1).
- [23] Zhe Xu, Lei Shi, Yijin Wang, et al. Pathological findings of COVID-19 associated with acute respiratory distress syndrome. *Lancet Respir Med* 2020. [https://doi.org/10.1016/S2213-2600\(20\)30076-X](https://doi.org/10.1016/S2213-2600(20)30076-X).
- [24] Chien JY, Hsueh PR, Cheng WC, et al. Temporal changes in cytokine/chemokine profiles and pulmonary involvement in severe acute respiratory syndrome. *Respirology* 2006;11:715–22. <https://doi.org/10.1111/j.1440-1843.2006.00942.x>.
- [25] Chu H, Zhou J, Wong BH, et al. Middle east respiratory syndrome coronavirus efficiently infects human primary T lymphocytes and activates the extrinsic and intrinsic apoptosis pathways. *J Infect Dis* 2016;213:904–14. <https://doi.org/10.1093/infdis/jiv380>.
- [26] Tisoncik JR, Korth MJ, Simmons CP, et al. Into the eye of the cytokine storm. *Microbiol Mol Biol Rev* 2012;76:16–32. <https://doi.org/10.1128/MMBR.05015-11>.
- [27] Kim KD, Zhao J, Auh S, et al. Adaptive immune cells temper initial innate responses. *Nat Med* 2007;13:1248–52. <https://doi.org/10.1038/nm1633>.
- [28] Liu J, Li S, Liu J, et al. Longitudinal characteristics of lymphocyte responses and cytokine profiles in the peripheral blood of SARS-CoV-2 infected patients. *medRxiv*, 2020. doi: <https://doi.org/10.1101/2020.02.16.20023671>.
- [29] Lu L, Shuang L, Manman X, et al. Risk factors related to hepatic injury in patients with corona virus disease 2019. *medRxiv preprint* doi: <https://doi.org/10.1101/2020.02.28.20028514>.
- [30] Bangash MN, Patel J, Parekh D. COVID-19 and the liver: little cause for concern. *Lancet Gastroenterol Hepatol* 2020. Published Online March 20, 2020. [https://doi.org/10.1016/S2468-1253\(20\)30084-4](https://doi.org/10.1016/S2468-1253(20)30084-4).
- [31] Fan Z, Chen L, Li J, et al. Clinical Features of COVID-19-Related Liver Damage. *bioRxiv*, 2020. doi: <https://doi.org/10.1101/2020.02.26.20026971>
- [32] The COVID-19 Investigation Team. First 12 patients with coronavirus disease 2019 (COVID-19) in the United States. *medRxiv preprint* doi: <https://doi.org/10.1101/2020.03.09.20032896>.
- [33] Huang Y, Gao Z. Study of the relationship SARS and hepatitis virus B. *Chin J Clin Hepatol* 2003;06:342–3.
- [34] Strnad P, Tacke F, Koch A, et al. Liver—guardian, modifier and target of sepsis. *Nat Rev Gastroenterol Hepatol* 2017;14:55–66.
- [35] Xiao Yong, Pan Hong, She Qian, Wang Fen, Chen Mingkai. Prevention of SARS-CoV-2 infection in patients with decompensated cirrhosis. *Lancet Gastroenterol Hepatol* 2020. [https://doi.org/10.1016/S2468-1253\(20\)30080-7](https://doi.org/10.1016/S2468-1253(20)30080-7).
- [36] Kumar D, Tellier R, Draker R, et al. Severe acute respiratory syndrome (SARS) in a liver transplant recipient and guidelines for donor SARS screening. *Am J Transplant* 2003;3:977–81.
- [37] Michaels MG, La Hoz RM, Danziger IL, et al. Coronavirus Disease 2019: Implications of Emerging Infections for Transplantation. *Am J Transplant* February 2020;ajt.15832. doi:10.1111/ajt.15832.
- [38] Andrea G, Daniele D, Barbara A, et al. Coronavirus disease 2019 and transplantation: a view from the inside. *Am J Transplant* 2020 Mar 17. <https://doi.org/10.1111/ajt.15853>.
- [39] Holshue Michelle L, DeBolt Chas, Lindquist Scott, Lofy Kathy H, Wiesman John, Hwang Hollianne, Spitters Christopher, Ericson Keith, Wilkerson Sara, Tural Ahmet, Diaz George, Cohn Amanda, Fox LeAnne, Patel Anita, Gerber Susan I,

- Kim Lindsay, Tong Suxiang, Lu Xiaoyan, Lindstrom Steve, Pallansch Mark A, Weldon William C, Biggs Holly M, Uyeki Timothy M, Pillai Satish K. First case of 2019 novel coronavirus in the United States. *N Engl J Med* 2020;382(10):929–36. <https://doi.org/10.1056/NEJMoa2001191>.
- [40] Leung WK, To KF, Chan PK, et al. Enteric involvement of severe acute respiratory syndrome associated coronavirus infection. *Gastroenterology* 2003;125:1011–7.
- [41] Chan JF-W, Yuan S, Kok K-H, et al. A familial cluster of pneumonia associated with the 2019 novel coronavirus indicating person-to-person transmission: a study of a family cluster. *Lancet* 2020;395:514–23.
- [42] Pan L, Mu M, Ren HG et al., Clinical characteristics of COVID-19 patients with digestive symptoms in Hubei, China: a descriptive, cross-sectional, multicenter study, *The American Journal of Gastroenterology*. Published online March 18, 2020
- [43] Wei XS, Wang X, Niu YR, et al. Clinical characteristics of SARS-CoV-2 infected pneumonia with diarrhea. *The Lancet Respiratory Medicine*-Manuscript Draft.
- [44] Zhang H, Kang ZJ, Gong HY, et al. The digestive system is a potential route of 2019-nCoV infection: a bioinformatics analysis based on single-cell transcriptomes. Preprint. Posted online January 30, 2020. bioRxiv 927806. doi: 10.1101/2020.01.30.927806.
- [45] Liang W, Feng Z, Rao S, et al. Diarrhoea may be underestimated: a missing link in 2019 novel coronavirus. *Gut* 2020;1–3. <https://doi.org/10.1136/gutjnl-2020-320832>.
- [46] Budden KF, Gellatly SL, Wood DL, et al. Emerging pathogenic links between microbiota and the gut-lung axis. *Nat Rev Microbiol*. 2017;15:55–63.
- [47] Liu Q, Wang R, Qu G, et al. Macroscopic autopsy findings in a patient with COVID-19. *J Forensic Med* 2020;36:1–3 (in Chinese).
- [48] Mao R, Liang J, Shen J, et al. Implications of COVID-19 for patients with pre-existing digestive diseases Published: March 11, 2020. DOI: [https://doi.org/10.1016/S2468-1253\(20\)30076-5](https://doi.org/10.1016/S2468-1253(20)30076-5).
- [49] Yeo C, Kaushal S, Yeo D. Enteric involvement of coronaviruses: is faecal–oral transmission of SARS-CoV-2 possible? *Lancet Gastroenterol Hepatol* 2020; published online Feb 19. [https://doi.org/10.1016/S2468-1253\(20\)30048-0](https://doi.org/10.1016/S2468-1253(20)30048-0).
- [50] Wu Y, Guo C, Tang L, et al. Prolonged presence of SARS-CoV-2 viral RNA in faecal samples. *Lancet Gastroenterol Hepatol* 2020. [https://doi.org/10.1016/S2468-1253\(20\)30083-2](https://doi.org/10.1016/S2468-1253(20)30083-2).
- [51] Xiao F, Tang M, Zheng X, Liu Y, Li X, Shan H. Evidence for gastrointestinal infection of SARS-CoV-2. *Gastroenterology* 2020. <https://doi.org/10.1053/j.gastro.2020.02.055>.
- [52] Yang J, Zheng Y, Gou X, et al. Prevalence of comorbidities in the novel Wuhan coronavirus (COVID-19) infection: a systematic review and meta-analysis. *Int J Infect Dis* 2020. <https://doi.org/10.1016/j.ijid.2020.03.017>.
- [53] Liang W, Guan W, Chen R, et al. Cancer patients in SARS-CoV-2 infection: a nationwide analysis in China. *Lancet Oncol* 2020 Mar;21(3):335–7. [https://doi.org/10.1016/S1470-2045\(20\)30096-6](https://doi.org/10.1016/S1470-2045(20)30096-6).
- [54] An P, Ji M, Ren H, et al. Protection of 318 inflammatory bowel disease patients from the outbreak and rapid spread of COVID-19 infection in Wuhan, China. Available at SSRN: <https://ssrn.com/abstract=3543590>
- [55] Chinese Society of IBD. Managing IBD patients during the outbreak of COVID-19. *Chin J Dig* 2020;40:E001.
- [56] Ianiro G, Mullish BH, Kelly CR, et al. Screening of faecal microbiota transplant donors during the COVID-19 outbreak: suggestions for urgent updates from an international expert panel. *Lancet Gastroenterol Hepatol* 2020. March 16, 2020. [https://doi.org/10.1016/S2468-1253\(20\)30082-0](https://doi.org/10.1016/S2468-1253(20)30082-0).
- [57] COVID-19: protecting health-care workers. *Lancet* 395 (10228) P922, MARCH 21, 2020. DOI: [https://doi.org/10.1016/S0140-6736\(20\)30644-9](https://doi.org/10.1016/S0140-6736(20)30644-9).
- [58] Tang JW, Li Y, Eames I, et al. Factors involved in the aerosol transmission of infection and control of ventilation in healthcare premises. *J Hosp Infect* 2006;64:100–14.
- [59] Wang C, Horby PW, Hayden FG, et al. A novel coronavirus outbreak of global health concern. *Lancet* 2020;395:470–3.
- [60] Gu Jinyang, Han Bing, Wang Jian. COVID-19: Gastrointestinal manifestations and potential fecal–oral transmission. *Gastroenterology* 2020. <https://doi.org/10.1053/j.gastro.2020.02.054>.
- [61] Repici A, Maselli R, Colombo M, et al. Coronavirus (COVID-19) outbreak: what the department of endoscopy should know. *Gastrointest Endosc* 2020. <https://doi.org/10.1016/j.gie.2020.03.019>.
- [62] Endoscopy activity and COVID-19: BSG and JAG guidance – update 20.03.20 <https://www.bsg.org.uk/covid-19-advice/endoscopy-activity-and-covid-19-bsg-and-jag-guidance/>. Accessed 20/3/2020
- [63] Zhang Y, Zhang X, Liu L, et al. Suggestions of Infection Prevention and Control in Digestive Endoscopy During Current 2019-nCoV Pneumonia Outbreak in Wuhan, Hubei Province, China. <http://www.worldendo.org/wp-content/uploads/2020/02/Suggestions-of-Infection-Prevention-and-Control-in-Digestive-Endoscopy-During-Current-2019-nCoV-Pneumonia-Outbreak-in-Wuhan-Hubei-Province-China.pdf>
- [64] ESGE and ESGENA Position Statement on gastrointestinal endoscopy and the COVID-19 pandemic. Update 1 (18.03.2020). <https://www.esge.com/esge-and-esgena-position-statement-on-gastrointestinal-endoscopy-and-the-covid-19-pandemic/>
- [65] European Centre for Disease Prevention and Control (ECDC). Personal protective equipment (PPE) needs in healthcare settings for the care of patients with suspected or confirmed novel coronavirus (2019-nCoV) 2020. Stockholm: ECDC; 2020. <https://www.ecdc.europa.eu/sites/default/files/documents/novel-coronavirus-personal-protective-equipment-needs-healthcare-settings.pdf>
- [66] Tse F, Bargaonkar M, Leontiadis G. COVID-19: Advice from the Canadian Association of Gastroenterology for Endoscopy Facilities, as of March 16, 2020. <https://www.cag-acg.org/images/publications/CAG-Statement-COVID-&-Endoscopy.pdf>
- [67] Geller C, Varbanov M, Duval RE. Human coronaviruses: insights into environmental resistance and its influence on the development of new antiseptic strategies. *Viruses* 2012;4(11):3044–68.
- [68] ASGE Quality Assurance in Endoscopy Committee, Calderwood AH, Day LW, Muthusamy VR, et al. ASGE guideline for infection control during GI endoscopy. *Gastrointest Endosc* 2018 May;87(5):1167–79.