



Since January 2020 Elsevier has created a COVID-19 resource centre with free information in English and Mandarin on the novel coronavirus COVID-19. The COVID-19 resource centre is hosted on Elsevier Connect, the company's public news and information website.

Elsevier hereby grants permission to make all its COVID-19-related research that is available on the COVID-19 resource centre - including this research content - immediately available in PubMed Central and other publicly funded repositories, such as the WHO COVID database with rights for unrestricted research re-use and analyses in any form or by any means with acknowledgement of the original source. These permissions are granted for free by Elsevier for as long as the COVID-19 resource centre remains active.



## Commentary

# A British Society of Thoracic Imaging statement: considerations in designing local imaging diagnostic algorithms for the COVID-19 pandemic



A. Nair<sup>a</sup>, J.C.L. Rodrigues<sup>b</sup>, S. Hare<sup>c</sup>, A. Edey<sup>d</sup>, A. Devaraj<sup>e</sup>, J. Jacob<sup>f,g</sup>,  
A. Johnstone<sup>h</sup>, R. McStay<sup>i</sup>, Erika Denton<sup>j</sup>, G. Robinson<sup>b,\*</sup>

<sup>a</sup> Department of Radiology, University College London Hospital, 235 Euston Road, London, NW1 2BU, UK

<sup>b</sup> Department of Radiology, Royal United Hospitals Bath NHS Foundation Trust, Combe Park, Bath, BA1 3NG, UK

<sup>c</sup> Department of Radiology, Royal Free London NHS Trust, Pond Street, London, NW3 2QJ, UK

<sup>d</sup> Department of Radiology, Southmead Hospital, North Bristol NHS Trust, Southmead Road, Bristol, BS10 5NB, UK

<sup>e</sup> Department of Radiology, The Royal Brompton & Harefield NHS Foundation Trust London, SW3 6NP, UK

<sup>f</sup> Department of Respiratory Medicine, University College London, London, NW1 2BU, UK

<sup>g</sup> Centre for Medical Image Computing, University College London, London, NW1 2BU, UK

<sup>h</sup> Department of Radiology, Leeds Teaching Hospitals NHS Trust, Leeds General Infirmary, Great George Street, Leeds, LS1 3EX, UK

<sup>i</sup> Department of Radiology, Freeman Hospital, Newcastle Upon Tyne Hospitals NHS Foundation Trust, Freeman Road, Newcastle Upon Tyne, NE7 7DN, UK

<sup>j</sup> Department of Radiology, Norfolk and Norwich University Hospital, Colney Lane, Norwich, NR4 7UY, UK

## ARTICLE INFORMATION

## Article history:

Received 10 March 2020

Accepted 11 March 2020

## Introduction

In accordance with guidance from the Chief Medical Officer's office and the Royal College of Radiologists, the British Society of Thoracic Imaging (BSTI) recognises that

based on the available evidence computed tomography (CT) currently has no upfront role in the diagnostic work-up of 2019 novel coronavirus (COVID-19) infection (<https://www.rcr.ac.uk/college/coronavirus-covid-19-what-rcr-doing/rcr-position-role-ct-patients-suspected-covid-19>). Nevertheless, a number of reports have been published highlighting CT appearances in COVID-19, raising the possibility of a role for CT in patient management.<sup>1–5</sup> In response to these reports, the BSTI published a preliminary consensus statement on 6 March 2020.<sup>6</sup> We discuss below what role, if any, CT would play in the detection and management of COVID-

\* Guarantor and correspondent: G. Robinson, Department of Radiology, Royal United Hospitals Bath NHS Foundation Trust, Combe Park, Bath, BA1 3NG, UK.

E-mail address: [grobison1@nhs.net](mailto:grobison1@nhs.net) (G. Robinson).

19 infection in the UK, and the logistics of imaging delivery. This role is heavily predicated on the clinical context as well as the timing of its intended use within the diagnostic pathway, especially relative to the current reference standard diagnostic test, real-time reverse transcriptase polymerase chain reaction (RT-PCR) of a pharyngeal swab,<sup>7</sup> and other clinical and laboratory investigations. Although it may not be feasible or desirable for isolation purposes to perform a chest radiograph (CXR), we should acknowledge that pragmatically patients with a respiratory complaint are likely to present via any number of routes (primary care, emergency departments [EDs] or outpatient clinics) having already had a CXR, other than to isolation pods outside a hospital, and work-up of a respiratory complaint would usually include a CXR in such settings. Cognizant of this fact, in the following discussion we have considered how a CXR would also fit into diagnostic algorithms, and in particular, how the use of CT would alter management in settings where a CXR was or was not available.

As such, we deliberate the following questions:

- (1) would a CT thorax contribute to management of symptomatic cases after a rapidly available RT-PCR result?
- (2) Would a CT thorax contribute to symptomatic cases if an RT-PCR test was not available or had to be rationed, and (a) a chest radiograph had been performed and was abnormal? (b) A chest radiograph had been performed and was normal, or was not/could not be performed?
- (3) Would a CT thorax contribute to the detection and management of COVID-19 in asymptomatic high-risk cases?
- (4) How should imaging (CT thorax or CXR) be provided?
- (5) What would a COVID-19 diagnostic algorithm look like?

In the following discussion, a high pre-test probability is assumed for symptomatic cases, based on one or more of: clinical presentation (Pyrexia of 37.8); acute onset persistent cough, hoarseness, nasal discharge or congestion, shortness of breath, sore throat, wheezing, sneezing; and compatible laboratory abnormalities (relative lymphopenia, elevated C-reactive protein [CRP]).<sup>8</sup>

### **Question 1: Would a CT thorax contribute to patient diagnosis after a rapidly available RT-PCR result?**

*If the RT-PCR result is positive*

CT findings in this setting would not change diagnosis and may be falsely negative in about 2–3% of RT-PCR positive symptomatic cases.<sup>2,5</sup> As such, we do not envisage a role for CT in this setting.

*If the RT-PCR result is negative*

In this setting, the role of CT is less certain. RT-PCR has a reported sensitivity of 60–70%<sup>2,5</sup> and thus approximately

30–40% of patients with COVID-19 infection could initially have a false-negative result. False-negative results may arise for a number of reasons including inadequate sampling technique or low viral load and thus many patients will require multiple testing to exclude the diagnosis. Ai *et al.* found that of 64 patients with initially negative RT-PCR testing, 15/64 (23.4%) had subsequent positive RT-PCR (mean time interval  $5.1 \pm 0.5$  days). Ten of these patients (i.e., only 15.6% of those with initial negative RT-PCR) had typical features on CT at the time of initial negative RT-PCR.<sup>5</sup> Fang *et al.* described a 29.4% rate of CT abnormality in patients with initially negative and subsequently positive RT-PCR.<sup>2</sup> As such, in the minority of patients with high clinical suspicion but negative initial RT-PCR, the presence of typical CT appearances, such as peripheral ground-glass opacity, could be used to rapidly diagnose COVID-19 infection, until such time as multiple negative testing is sufficient to exclude or change the diagnosis.

Conversely, it is important to note that a normal CT cannot be used to exclude a diagnosis of COVID-19 when duration of symptoms is short,<sup>9</sup> although there is some evidence to suggest that the negative predictive value of CT is higher when symptom duration is >1 week.<sup>10,11</sup> Nevertheless, even in this scenario, multiple PCR testing should be the preferred method to exclude the diagnosis if no limitation on PCR testing (both availability and turn around times) exists.

Some CT characteristics, such as pleural effusion, lymphadenopathy, and tree-in-bud nodularity, have been reported as uncommon in COVID-19 and the presence of these features should prompt for evaluation of alternative diagnoses.

Therefore, we regard the role of CT in COVID-19 confirmed cases following RT-PCR results to be the same as in any other viral infection, in that it could be used to: (1) find co-existing or underlying diagnoses; (2) help diagnose complications, or investigate a clinically discordant picture (e.g., CRP decline, but increasing hypoxia); and (3) add value in patients with pre-existing lung diseases.

Even if CT is used to aid rapid diagnosis, it needs to be made clear how this would translate into a change in management. A practical strategy for patients with initially negative RT-PCR could involve triage into the following categories: (1) self-isolation at home for those with no CT abnormality, with serial testing later to definitively exclude the diagnosis; (2) self-isolation or hospital isolation (depending on clinical status) for patients with typical CT appearances; and (3) urgent evaluation for alternative diagnoses, while still maintaining isolation, for patients with non-typical CT abnormalities.

It certainly could be argued, however, that a combination of clinical, laboratory and CXR findings could also be used to triage patients with suspected COVID-19 requiring hospital admission in the first instance, reserving CT for challenging situations. The relative proportions of patients in each triage category would probably differ, given the increased sensitivity of CT for COVID-19, but we are unaware of any data comparing the sensitivity of CT to a combination of CXR and laboratory findings to shed any further light on the

relative merits of these different strategies. A study by Xiong *et al.* offers a compelling argument for such a strategy: in their analysis of 42 patients, clinical findings and white blood cell count were not well-correlated with initial CT findings, but CRP, erythrocyte sedimentation rate (ESR), and serum lactate dehydrogenase (LDH) were significantly moderately to strongly correlated with the extent and severity of overall involvement and the size of the largest CT lesion.<sup>10</sup>

The use of CT as the main diagnostic tool for COVID-19 over and above RT-PCR in China has been subsequently challenged.<sup>12</sup> It is noteworthy that the fifth edition of the *Diagnosis and Treatment Program of 2019 New Coronavirus Pneumonia* proposed by The National Health Commission of China included chest CT findings as a diagnostic criterion,<sup>13</sup> but CT was removed in the more recent sixth and seventh versions,<sup>14,15</sup> reflecting the extremely dynamic nature of consensus opinion on this subject.

## Question 2: Would a CT thorax contribute to symptomatic cases if an RT-PCR test was not available or had to be rationed?

A limited or exhausted supply of RT-PCR testing kits is not inconceivable. Even if a robust supply was in place, other factors, such as interruption of transport infrastructure and availability of sufficient virology capacity, or the limited number of centres that could process results, could impede the utility of this test. We consider the following two scenarios.

*If a chest radiograph had been performed and was abnormal*

It is salutary that CXR may be abnormal in the majority of COVID-19 cases, especially severe cases,<sup>16,17</sup> with severity defined according to standard definitions.<sup>18</sup> Huang *et al.* found bilateral radiographic abnormalities in 40/41 (98%) of cases<sup>16</sup>; Guan *et al.* found radiographic abnormalities in 162/274 patients (59.1%), but CXR was more likely to be abnormal in severe disease (46/60 [76.7%] with severe disease, versus 116/214 [54.2%] of non-severe disease).<sup>17</sup> Conversely, CT thorax has a very low specificity, approximately 25%, for COVID-19.<sup>5</sup> Furthermore, CRP is abnormally elevated in between 61% to 92% of patients.<sup>17,19</sup> As such, we do not consider a CT thorax to provide additive benefit to diagnosis over and above high clinical suspicion, laboratory findings, and typical radiographic abnormalities in this setting. Further work is needed to understand the potential role of CT in providing prognostic information, in particular in patients with severe disease, including guiding management of patients recovering from severe disease.

*If a chest radiograph had been performed and was normal, or was not/could not be performed*

In this setting, the lack of initial RT-PCR testing availability could necessitate an alternative test. A CT thorax could then be viewed as the optimum initial diagnostic tool

for all the reasons discussed in Question 1. Assuming it becomes necessary to elevate CT thorax to this position in the diagnostic work-up, the role of CT thorax in guiding management would be to triage patients into the categories discussed earlier (self-isolation at home with repeat testing as necessary, admission and isolation, or evaluation for alternative diagnoses and potentially aiding triage of unwell patients).

In Table 1, we illustrate the possible use of CT as a triage mechanism prior to initial RT-PCR results being available. For all scenarios, we have further assumed that, regardless of the presence or absence of initial radiographic abnormalities, initial management would necessitate isolation and standard care given high clinical suspicion. Furthermore, if a chest radiograph suggests an alternative diagnosis (such as lobar pneumonia), the CT may provide no additional pragmatic benefit over and above clinical suspicion and RT-PCR results, and as such, we do not consider it beneficial to explore the permutations of that scenario.

## Question 3: Would a CT thorax contribute to the detection and management of COVID-19 in asymptomatic high-risk cases?

Data on the prevalence of CT abnormalities, and thus the accuracy of CT, in detecting COVID-19 in asymptomatic contacts of positive or confirmed cases are scarce. At the time of writing, we are aware of only two publications on the subject. Hu *et al.*<sup>20</sup> evaluated the laboratory and CT characteristics of 24 asymptomatic close contacts who were COVID-19 carriers, as confirmed by RT-PCR. Seventeen of 24 (70.8%) had CT abnormalities, with 12 (50% of total) showing typical peripheral ground-glass opacity. The minority had lymphopenia (16.8%) and elevated CRP (17.4%). The 17 patients with CT abnormalities were older (median age 38 versus 14 years old,  $p=0.012$ ). A more recent analysis by Inui *et al.* of 112 RT-PCR confirmed cases of COVID-19 from the cruise ship “Diamond Princess” demonstrated CT abnormalities in only 44/82 (54%) asymptomatic cases (reference <https://doi.org/10.1148/ryct.202000110>). In combination, this reinforces the unsuitability of CT in isolation as a screening tool for this subgroup. Even if CT were to be used to screen close contacts, we cannot envisage the practical value of such a strategy, compared to serial RT-PCR testing (as long as the latter is available), given that such contacts would be advised to self-isolate. In addition, the specificity of CT or RT-PCR for screening asymptomatic contacts in this manner is undefined.

## Question 4: HOW should imaging (CT thorax or chest radiography) be provided?

Inevitably, the provision of imaging will depend on local protocols for isolation and identification of suspected COVID-19 patients when they first present; however, we consider the following broad options. Regardless of the option, the need to perform a comprehensive clean of equipment between patients (to protect negative patients

**Table 1**

Possible impact of computed tomography (CT) on the diagnosis of COVID-19, assuming no RT-PCR result is available initially.

Scenario no.	CT findings for COVID-19	CT-based triage category <sup>a</sup>	Initial RT-PCR result	Would a rapidly available RT-PCR have voided the CT result?	Management post-initial RT-PCR result	Repeat RT-PCR result (if obtained) (4–10 days)	Management following repeat RT-PCR result
1	Typical	Isolation ± admission	Positive	Yes <sup>b</sup>	Unchanged	Positive	Unchanged
2	Typical	Isolation ± admission	Positive	Yes <sup>b</sup>	Unchanged	Negative	Unchanged: in this subgroup, 60% of cases show imaging features prior or parallel to RT-PCR positivity, and the subsequent negative RT-PCR does not decrease clinical probability of COVID-19 infection; however, the role of CT in evaluating response in conjunction with RT-PCR requires further work
3	Typical	Isolation ± admission	Negative	No <sup>c</sup>	Unchanged	Positive	Unchanged: 16–29% of patients with initial negative RT-PCR could have positive typical CT findings. Possible downgrade; may be considered COVID-19 negative. Repeat CT in this scenario may also have a role in guiding management along with clinical evaluation.
4	Typical	Isolation ± admission	Negative	No	Downgrade to self-isolation depending on clinical status, await repeat RT-PCR	Negative	Unchanged
5	Clear	Self-isolation, do not admit	Positive	Yes <sup>b</sup>	Possible upgrade to admission depending on clinical status. Negative CT may indicate non-severe disease. Whether this independently impacts prognosis requires further work	Positive	Unchanged
6	Clear	Self-isolation, do not admit	Positive	Yes <sup>b</sup>	Possible upgrade to admission depending on clinical status. Whether this independently impacts prognosis requires further work	Negative	Unchanged: RT-PCR results would be guiding management here, and a negative follow-up RT-PCR result does not exclude COVID-19 infection; however, the role of CT in evaluating response in conjunction with RT-PCR requires further work
7	Clear	Self-isolation, do not admit	Negative	No <sup>c</sup>	Unchanged	Positive	Possible upgrade: depending on symptom duration, initial CT could be negative
8	Clear	Self-isolation, do not admit	Negative	Yes <sup>b</sup>	Unchanged	Negative	Possible downgrade; may be considered COVID-19 negative. In some clinical scenarios, CT may have a role in determining the frequency and prioritisation of repeat testing, and the level of cohort isolation required, all of which requires further consensus.

<sup>a</sup> The decision to admit will be based on clinical and laboratory parameters.<sup>b</sup> CT demonstration of underlying lung disease or alternative diagnosis could still be useful.<sup>c</sup> RT-PCR would be false-negative in this scenario.

from positive ones), and the implications that has for throughput, should be recognised.

#### *Mobile CXR unit alongside dedicated COVID-19 assessment area located outside the main hospital building*

A mobile unit set up in this way would be able to maintain high throughput and fast image transfer and interpretation. Such a strategy may, with the agreement of local respiratory and infectious diseases teams, even obviate

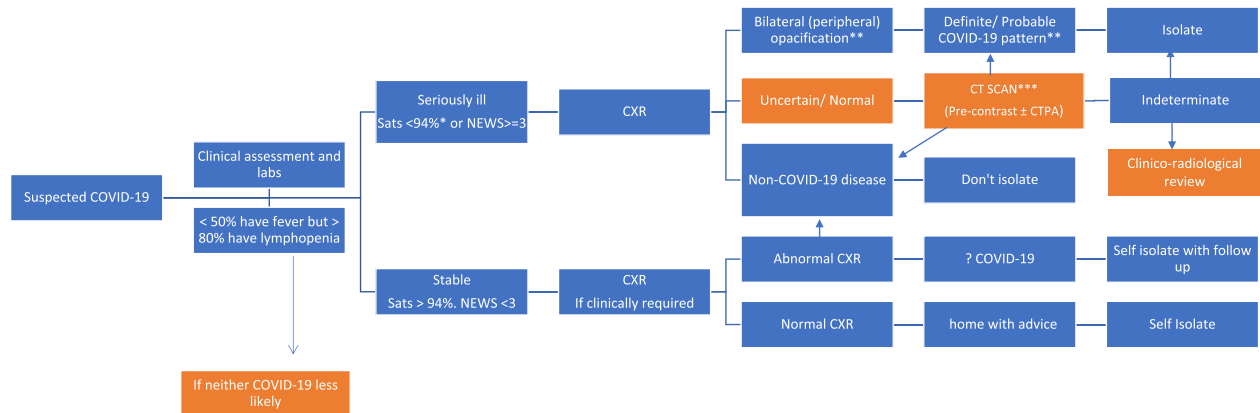
the need for CT thorax, but only if (a) RT-PCR testing and results are available rapidly; and (b) there is still an intention to isolate and treat patients with negative CXR and RT-PCR but high pre-test probability.

#### *Mobile CT scanner unit alongside dedicated COVID-19 assessment area located outside the main hospital building*

A CT unit set up in this way would also allow high throughput, as the type of CT required for diagnosis is



# Radiology decision tool for suspected COVID-19



\*94% unless known COPD in which case <90%

\*\* Unsuspected/ unexpected cases may be incidentally discovered on CXR/ CT at this stage; should be reviewed in the context of clinical suspicion as to likelihood of COVID-19.

\*\*\*Classic and Indeterminate CTs should be scored either: 'mild' or 'moderate/severe'

**Figure 1** Bsti/NHSE Radiology decision tool for suspected COVID-19 (available at <https://www.bsti.org.uk/standards-clinical-guidelines/clinical-guidelines/bsti-nhse-covid-19-radiology-decision-support-tool/>).

easy and rapid to perform (unenhanced thoracic CT). Image transfer and interpretation would take longer relative to CXR, but rapid reporting turnaround could be aided by structured reporting templates for relevant abnormalities only. Examples of such templates are provided on the Bsti website at [bsti.org.uk](http://bsti.org.uk). Such a CT set-up realistically obviates the need for mobile CXR provision.

## Mobile CT scanner in a community location

It may be desirable to locate CT scanners in community locations away from the hospital or take advantage of existing community-located scanners. Adequate operating procedures to ensure rapid transmission of images to designated reporting centres would be required in such cases.

## ED CT/CXR for COVID-19 patients, mobile CT/CXR for routine ED imaging

As patients with COVID-19 may bypass the dedicated assessment area and present to ED itself, this strategy would allow imaging to be performed without potentiating transmission to other ED attendees via the scanner. Regular ED work could be transferred to mobile scanners alongside the ED; however, such a strategy would not obviate the need for local cleaning procedures. In addition, logistically, such a set-up would be challenging due to default image transfer protocols and worklist interactions between ED scanners, radiology information systems (RIS) and picture archiving and communications systems (PACS).

## Fixed site non-ED CT scanner

For trusts where CT scanner(s) are solely based within the radiology department contingency plans for “scanner

downtime” during deep cleans and policies to minimise cross-contamination would need to be instigated. An alternative would be for trusts to consider a mobile CT scanner unit outside the hospital; however, for inpatients with suspected or confirmed COVID-19 infection who require further imaging, such as CT pulmonary angiography, or for very unwell patients, a fixed site ED or non-ED CT scanner would be the only options. In this circumstance, it may be pragmatic to ring-fence consecutive slots for the confirmed COVID-19 cases on the nominated scanner to make cleaning more practical.

## Question 5: What would a COVID-19 diagnostic algorithm look like

Figure 1 illustrates the diagnostic work-up algorithm now endorsed by the British Society of Thoracic Imaging, Dr Cliff Mann, National Clinical Director of Urgent and Emergency Care, Dr Matt Inada-Kim, National Clinical Advisor in Sepsis and Deterioration, and Professor Erika Denton, National Clinical Director for Diagnostics. The algorithm consolidates the foregoing discussion on the role of imaging by (1) placing clinical and laboratory assessment, and the patient's clinical condition, at its centre; (2) using CXR as the initial diagnostic imaging tool; and (3) suggesting a potential role for CT in cases with a normal or indeterminate CXR.

## Conclusion

The putative role of CT in the diagnosis, triage, and prognostication of patients with COVID-19 infection continues to be refined. We explore scenarios integrating CT into the diagnostic algorithm; however, the clinical value of

this integration, compared to alternative strategies incorporating quick and immediately scalable standard clinical and laboratory assessment (even in the absence of RT-PCR availability) is unknown, because published studies on thoracic CT in COVID-19 infection to date have, frustratingly, described these assessments without analysing their relative merit as part of an alternative diagnostic strategy. In the absence of such data, we can only reiterate the need for strategic thinking that explores all available options to achieve maximum public benefit, optimise throughput in the shortest timeframe, and minimise detriment.

## Declaration of Competing Interest

The authors declare no conflict of interest.

## Acknowledgements

J.J. reports fees from Boehringer Ingelheim and Roche unrelated to the current submission and is supported by a Clinical Research Career Development Fellowship 209553/Z/17/Z from the Wellcome Trust. A.N. reports part funding from the UCL NIHR Biomedical Research Centre, and a medical advisory role with Aidence BV, an artificial intelligence company. The authors would also like to thank Professor Simon Padley, Clinical Director of Radiology, the Royal Brompton Hospital, and Professor Nicola Sverzellati, Department of Radiology, University of Parma, Italy, for their contribution to the BSTI/NHSE Radiology decision tool for suspected COVID-19.

## References

1. Chung M, Bernheim A, Mei X, et al. CT imaging features of 2019 novel coronavirus (2019-nCoV). *Radiology* 2020:200230.
2. Fang Y, Zhang H, Xie J, et al. Sensitivity of chest CT for COVID-19: comparison to RT-PCR. *Radiology* 2020:200432.
3. Fang Y, Zhang H, Xu Y, et al. CT manifestations of two cases of 2019 novel coronavirus (2019-nCoV) pneumonia. *Radiology* 2020:200280.
4. Xu X, Yu C, Qu J, et al. Imaging and clinical features of patients with 2019 novel coronavirus SARS-CoV-2. *Eur J Nucl Med Mol Imaging* 2020.
5. Ai T, Yang Z, Hou H, et al. Correlation of chest CT and RT-PCR testing in coronavirus disease 2019 (COVID-19) in China: a report of 1014 cases. *Radiology* 2020:200642.
6. COVID-19: statement from the British society of thoracic imaging (BSTI). Last updated on 6 March 2020. Available at: <https://www.bsti.org.uk/standards-clinical-guidelines/clinical-guidelines/covid-19-bsti-statement-and-guidance/>. [Accessed 6 March 2020].
7. World Health Organization. Clinical management of severe acute respiratory infection when novel coronavirus (2019-nCoV) infection is suspected: interim guidance. Last updated on 28 January 2020. Available at: [https://www.who.int/publications-detail/clinical-management-of-severe-acute-respiratory-infection-when-novel-coronavirus-\(ncov\)-infection-is-suspected](https://www.who.int/publications-detail/clinical-management-of-severe-acute-respiratory-infection-when-novel-coronavirus-(ncov)-infection-is-suspected). [Accessed 9 March 2020].
8. Zhang J, Zhou L, Yang Y, et al. Therapeutic and triage strategies for 2019 novel coronavirus disease in fever clinics. *Lancet Respir Med* 2020.
9. Bernheim A, Mei X, Huang M, et al. Chest CT findings in coronavirus disease-19 (COVID-19): relationship to duration of infection. *Radiology* 2020:200463.
10. Xiong Y, Sun D, Liu Y, et al. Clinical and high-resolution CT features of the COVID-19 infection: cochanges. *Invest Radiol* 2020.
11. Pan F, Ye T, Sun P, et al. Time course of lung changes on chest CT during recovery from 2019 novel coronavirus (COVID-19) pneumonia. *Radiology* 2020:200370.
12. Yang W, Yan F. Patients with RT-PCR confirmed COVID-19 and normal chest CT. *Radiology* 2020:200702.
13. General Office of National Health Committee. Office of state administration of traditional Chinese medicine. Notice on issuing a new coronary virus pneumonia diagnosis and treatment plan (trial implementation of revised fifth edition). Last updated on 8 February 2020. Available at: <http://www.nhc.gov.cn/xcs/zhengcwj/202002/d4b895337e19445f8d728fcaf1e3e13a.shtml>. [Accessed 9 March 2020].
14. General Office of National Health Committee. Office of state administration of traditional Chinese medicine. Notice on issuing a new coronary virus pneumonia diagnosis and treatment plan (trial implementation of revised sixth edition). Last updated on February 18, 2020. Available at: <http://www.nhc.gov.cn/xcs/zhengcwj/202002/8334a8326dd94d329df351d7da8aefc2.shtml>. [Accessed 9 March 2020].
15. General Office of National Health Committee. Office of state administration of traditional Chinese medicine. Notice on issuing a new coronary virus pneumonia diagnosis and treatment plan (trial implementation of revised seventh edition). Last updated on 3 March 2020. Available at: <http://www.nhc.gov.cn/xcs/zhengcwj/202003/46c9294a7dfe4cef80dc7f5912eb1989.shtml>. [Accessed 9 March 2020].
16. Huang C, Wang Y, Li X, et al. Clinical features of patients infected with 2019 novel coronavirus in Wuhan, China. *Lancet* 2020;395:497–506.
17. Guan WJ, Ni ZY, Hu Y, et al. Clinical characteristics of coronavirus disease 2019 in China. *N Engl J Med* 2020.
18. Metlay JP, Waterer GW, Long AC, et al. Diagnosis and treatment of adults with community-acquired pneumonia. An official clinical practice guideline of the American Thoracic Society and Infectious Diseases Society of America. *Am J Respir Crit Care Med* 2019;200:e45–67.
19. Zhang JJ, Dong X, Cao YY, et al. Clinical characteristics of 140 patients infected with SARS-CoV-2 in Wuhan, China. *Allergy*; 2020.
20. Hu Z, Song C, Xu C, et al. Clinical characteristics of 24 asymptomatic infections with COVID-19 screened among close contacts in Nanjing, China. *Sci China Life Sci* 2020.