



Since January 2020 Elsevier has created a COVID-19 resource centre with free information in English and Mandarin on the novel coronavirus COVID-19. The COVID-19 resource centre is hosted on Elsevier Connect, the company's public news and information website.

Elsevier hereby grants permission to make all its COVID-19-related research that is available on the COVID-19 resource centre - including this research content - immediately available in PubMed Central and other publicly funded repositories, such as the WHO COVID database with rights for unrestricted research re-use and analyses in any form or by any means with acknowledgement of the original source. These permissions are granted for free by Elsevier for as long as the COVID-19 resource centre remains active.



Editorial

The continuing evolution of COVID-19 imaging pathways in the UK: a British Society of Thoracic Imaging expert reference group update

Introduction

In December 2019, Wuhan City (Hubei Province, China) reported a febrile respiratory tract illness of unknown origin in a cluster of patients. Bronchoalveolar lavage of the patients isolated a novel strain of coronavirus (SARS-coronavirus-2 [SARS-CoV-2]) as the pathogen.¹ The pulmonary infection caused by SARS-CoV-2 was named coronavirus disease 2019 (COVID-19) by the World Health Organization (WHO). Despite the imposition of strict quarantine rules and restricted travel within and from China, the infection has spread rapidly across the globe, with continuing escalation in the UK, necessitating a plan by NHS England to build several temporary “Nightingale” hospitals (of up to 4,000 beds each), to provide mass-scale extra capacity.

Following on from three initial statements^{2–4} this Editorial from the British Society of Thoracic Imaging (BSTI) will collate ongoing knowledge, guidance, and developing conundrums related to COVID-19 imaging.

COVID-19 chest radiograph reporting template

The unprecedented surge in UK COVID-19 cases has seen the chest radiograph (CXR) emerge as the frontline diagnostic imaging test,⁵ in conjunction with clinical history and key blood biomarkers: C-reactive protein (CRP) and lymphopenia. In early March 2020, BSTI developed a simple, internationally recognised CXR reporting template to help facilitate standardised reporting with embedded CXR reporting codes allowing retrospective radiology information system keyword searches for audit purposes⁶ (Electronic Supplementary Material Appendix S1).

This template stratifies patients into one of four groups based on CXR findings: classic/probable COVID-19 findings (Fig 1); indeterminate for COVID-19 (Fig 2); normal (COVID-19 not excluded in the correct clinical context);

and features most consistent with a non-COVID-19 diagnosis (Fig 3). Frontline doctors have found this a useful adjunct to clinical assessment, particularly when CXRs are “hot-reported”. More nuanced severity grades can also be applied, in particular for the classic/probable COVID-19 CXRs: these include a simple qualitative scoring method (mild, moderate, severe) or the quantitative modified Radiographic Assessment of Lung Edema (RALE) scoring system.⁷

COVID-19 CT reporting template

Several authors⁸ and professional societies have agreed computed tomography (CT) should not be used as a first-line or pure diagnostic test. Although sensitive, CT findings of COVID-19 are not specific. In addition, false-negative

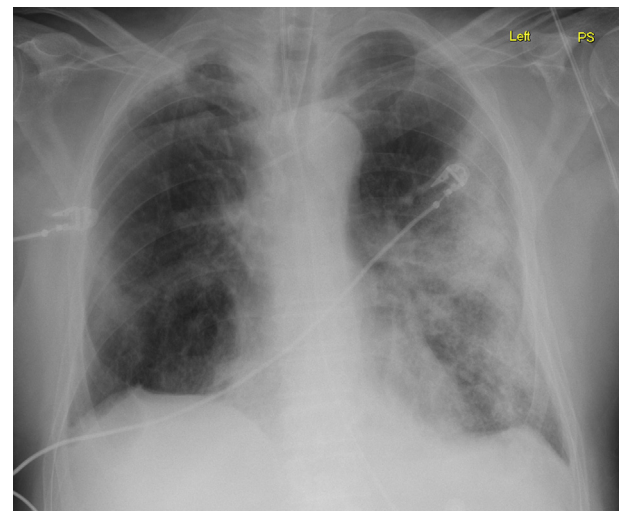


Figure 1 A 68-year-old intubated man with fever and cough. Classic COVID-19 appearances on CXR. This patient had a positive RT-PCR for COVID-19 on the second throat swab after an initial negative throat swab.

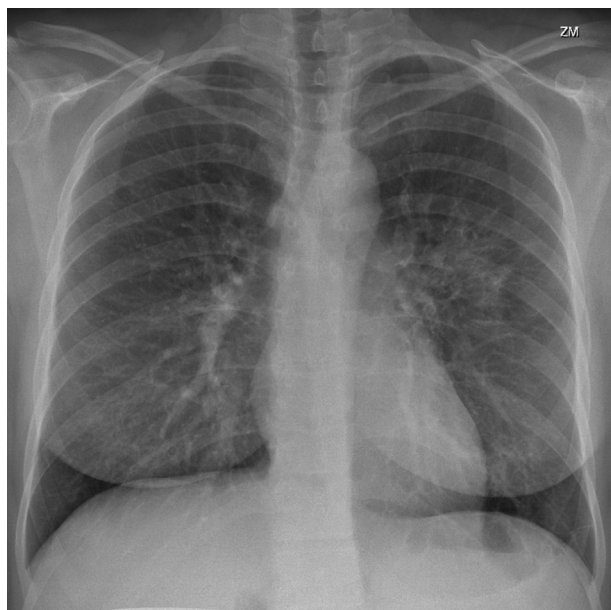


Figure 2 A 39-year-old woman with fever and ill-defined left perihilar opacity. The RT-PCR throat swab was COVID-19 positive.

CT rates vary in the literature, ranging from 3–56% in reverse transcriptase (RT)-polymerase chain reaction (PCR)-positive patients.⁹ In contrast, mainland China frequently employed CT as a first-line investigation for COVID-19; however, such practice was burdensome on radiology departments and hugely challenging for infection control. It is also noteworthy that the use of CT as the main diagnostic tool for COVID-19 over and above RT-PCR in China has been challenged subsequently.¹⁰ Moreover, use of chest CT findings as a diagnostic criterion were removed in the more

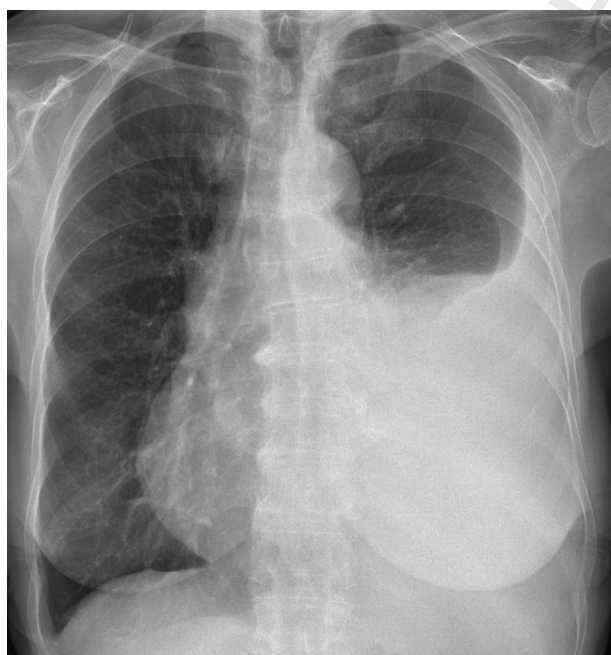


Figure 3 A 77-year-old woman with large left pleural effusion and no significant alveolar opacity. The CXR revealed a non-COVID diagnosis.

recent sixth and seventh editions of the *Diagnosis and Treatment Program of 2019 New Coronavirus Pneumonia* proposed by The National Health Commission of China.⁴ CT in COVID-19 shows typical findings of ground-glass opacity, peripheral consolidation, or a combination of both. Ai *et al.* reported CT sensitivity from their Wuhan cohort of 97% when compared to RT-PCR.¹¹ In light of this conflicting evidence, BSTI issued a statement on the potential role of CT in COVID-19, highlighting that any design of local diagnostic imaging algorithms would be contingent on RT-PCR sensitivity (dependent upon both the assay and the technique) and turnaround times,⁴ which have geographical variation. At the time of writing, the UK government is planning on increasing RT-PCR testing 10-fold, to approximately 25,000 tests a day.¹²

Where CT does emerge as important is in the BSTI/NHS England COVID-19 diagnostic algorithm ([Electronic Supplementary Material Appendix S2](#)). Patients who are unwell with an indeterminate or normal CXR may then be considered for CT imaging. This will help decide subsequent management and need for isolation. CT can also be justifiably used in a cohort of patients with high clinical probability but suspected false-negative RT-PCR results.

In early March, BSTI suggested a CT reporting template⁶ ([Electronic Supplementary Material Appendix S3](#)) that could help as a guide to facilitate consistency of reporting. This has recently been simplified. It should be noted that CT severity scoring is not validated as linked to potential outcomes in COVID-19 and should be reserved, if used, for qualitative assessment of parenchymal involvement. Further potential templates for CXR and CT in the intensive care setting are also included in this paper for reference ([Electronic Supplementary Material Appendices S4 and S5](#)).

When performed, a low-dose unenhanced CT (LDCT) technique should be utilised and consideration given to an additional CT pulmonary angiogram (PA; if renal function permits).⁶ The need for CTPA is to ensure occult pulmonary embolism (PE) is excluded, particularly in light of increasing reports of pro-thrombotic risk in COVID-19. The unenhanced LDCT prior is performed for two main reasons¹: dependent ground glass is often exaggerated on contrast-enhanced CT and can be mistaken for true ground glass²; having a baseline unenhanced examination can be useful if subsequently performing unenhanced imaging to look for fibrosis. It is also recognised that on-table “hot” review of lung windows, including lung bases on CT abdominal examinations, can be beneficial. Such rapid review permits quick detection of incidental COVID-19 cases on designated “clean” scanners, allowing appropriate decontamination.

Three-step imaging requesting tool

With RT-PCR turnaround times at >24–48 h in large portions of the country, CRP, lymphocyte count, and CXR have emerged as the bedrock of COVID-19 patient triage.¹³ Evidence from the current UK epicentre, London, indicates that several patients undergoing imaging investigations for other indications, including for abdominal pain in the

absence of respiratory symptoms, frequently demonstrate COVID-19 pulmonary features on CT. This “unexpected” COVID-19 diagnosis on CT has necessitated stricter vetting strategies for all imaging requests with the aim of avoiding further exacerbation of COVID-19 spread amongst staff and COVID-19 naive patients. Such is the fear around contaminating non-infected patients with COVID-19 on supposedly “clean” CT machines, stringent vetting of imaging requests is essential. We suggest a three-step triage tool ([Electronic Supplementary Material Appendix S6](#)), developed in collaboration with the Royal Free London NHS Trust (RFL NHS Trust), provides a simple, effective method of screening patients who are referred for imaging:

- (1) Does the patient have a new cough or fever? Yes or No
- (2) Is there a lymphopenia or raised CRP? Yes or No
- (3) Is the CXR consistent with COVID-19? Yes or No

This tool has allowed radiology departments to triage imaging requests to determine whether they should take place on the designated “COVID” or the “clean” CT machine. The tool can also be incorporated into digital imaging requesting systems as a mandated field.

The role of CT in COVID-19 infection control management

An emerging bottleneck to effective care is dealing with hospital isolation capacity. Inpatients who are truly RT-PCR negative can be moved to a non-isolation ward, freeing up isolation beds for confirmed COVID-19 positive patients, also reducing the risk of virus transmission within the hospital setting. Patients with a high index of clinical suspicion of COVID-19, but who test negative on initial RT-PCR test, continue to be managed with respiratory isolation precautions, often undergoing repeat RT-PCR testing; however, this means yet further delay whilst awaiting test results.

A further concern being recognised regarding de-isolation is patient discharge to either home or community care: a confirmed COVID-19 diagnosis or a confirmed non-COVID-19 diagnosis is key to impart infection control advice to both families and carers of discharged patients.

With stepdown from isolation to de-isolation beds becoming a rate-limiting step, an effective pathway to deal with negative RT-PCR results in the setting of high clinical probability of COVID-19 infection has been developed at the RFL NHS Trust ([Electronic Supplementary Material Appendix S7](#)).¹⁴ This pathway, which is predicated on two negative RT-PCR tests and two normal/indeterminate CXRs in the setting of high clinical probability of COVID-19 infection, facilitates a systematic approach to patient de-isolation and stepdown from the COVID ward to non-COVID wards, whilst also providing a means to exclude an alternative diagnosis.

CT chest imaging in the acute emergency surgical abdomen

In the patient with a surgical abdomen requiring potential emergency surgery, intubation and ventilation could generate COVID-19 aerosols. Some reports have also emerged of increased mortality in COVID-19-positive patients undergoing surgery.¹⁵ As such, BSTI and the British Society of Gastrointestinal and Abdominal Radiology (BSGAR) have suggested a template for this scenario ([Electronic Supplementary Material Appendix S8](#)).

A complete CT thorax is advocated if the clinical decision has already been made to send the patient for a CT abdomen and pelvis. It should be stressed, however, that this recommendation does not apply to patients in whom abdominal CT (or magnetic resonance imaging [MRI]) is being performed for other reasons, or electively, and that this pathway is purely to facilitate decisions in severely unwell patients where the clinical diagnosis of an acute abdomen is requires emergency surgery.

BSTI disagrees with current Intercollegiate General Surgery Guidance on COVID-19,¹⁶ which recommends that “any patient undergoing abdominal CT scan should also have a CT chest”. As previously mentioned, we do not advocate CT chest screening for COVID-19 (indeed neither is there a role for multiple RT-PCR testing in asymptomatic individuals). CT chest is only 54% sensitive in asymptomatic patients who are RT-PCR positive for COVID-19.¹⁷ Therefore, a negative CT thorax cannot be considered to have sufficient negative predictive value to exclude COVID-19; however, in the context of an emergent surgical abdomen, a negative CT thorax, as well as low clinical probability of COVID-19, could aid the confidence in the surgical decision to take the patient to theatre or manage the patient conservatively.

Other situations where CT screening has been notionally considered include prior to non-emergency surgery; interventional radiology mechanical thrombectomy for proximal vessel occlusion in ischaemic stroke; and primary percutaneous coronary intervention for ST-elevation myocardial infarction. The general principles regarding “CT screening” hold true for these cohorts: there is a significant risk of a false-negative study, resulting in inappropriate reassurance and the risk of a patient potentially being denied treatment for findings that are not specific for COVID-19. It is also important to emphasise that it remains uncertain how CT manifestations correlate with COVID-19 “infectivity”. Even if there were CT changes compatible with COVID-19, it would not necessarily be possible to determine where that patient lies in the temporal evolution of the changes with a single time-point analysis and changes may persist on CT for >28 days.¹⁸

BSTI/NHSX collaboration

When confronted by a new disease, sharing data and expertise is essential to maintain homogeneous diagnostic and management standards across a country. This is

particularly true in a condition such as COVID-19 where imaging has a central diagnostic role. Given the scale of the pandemic, radiology workforces have been configured so that non-chest specialist radiologists now have to report chest imaging. It has become apparent that rapid deployment of technology to upskill the UK radiology workforce in COVID-19 imaging interpretation is both necessary and urgent.

Although, in theory, existing image transfer capabilities across the NHS should have facilitated widespread data sharing across sites, in practice, this has never been coordinated on a regional or national scale in the UK. The transfer of imaging studies directly from a picture archiving and communications system (PACS) viewer to a central imaging repository would make teaching and research in the NHS more efficient and accurate.³ By bringing together thoracic CT expertise across the UK, a central COVID-19 imaging repository and database could help reduce unwarranted diagnostic variation, thereby providing better quality of care for patients, and provide a resource to accumulate up-to-date information in a rapidly changing clinical setting.

Through a partnership with NHSX, BSTI have created a national database of CXR and CT images alongside a linked clinical dataset. The purpose of the National COVID-19 Chest Imaging Database (NCCID) initiative is to enable the development and validation of artificial intelligence technologies in the domains of medical image analysis and data science and the enabling of research projects in response to the COVID-19 pandemic. Further to the creation of a database, NHSX will be able to accelerate the adoption of technologies that may prove effective in supporting COVID-19 care pathways. Our anticipation is that these data will help influence management decisions during the COVID-19 pandemic in “real time”.

With the recognition that front-line clinical staff will have to prioritise patient management, the NCCID initiative has been built to run without significant input from clinical teams. Images can be uploaded by hospital PACS teams through the Image Exchange Portal network. Clinical data will be collected by research staff, who have been redeployed for COVID-19-related research, and uploaded to a parallel central repository linked to imaging data. In time, more formal linkage with other clinical COVID-19 databases is anticipated. In addition to data, the NCCID resource also aims to link researchers asking similar clinical questions around the country. We hope to bring the brightest minds to work on the challenges posed by COVID-19. By doing this on a national level, we hope to speed up scientific discovery by utilising economies of scale and resource across UK institutions and researchers.

Emerging imaging conundrums in COVID-19: pulmonary embolism in COVID-19

Most of the published CT literature in COVID-19 has been in unenhanced CT; however, there is increasing concern about venous thromboembolism (VTE) risk in COVID-19.

Acute pulmonary embolism (PE) could be incidental or related to COVID-19. Within the latter, this might be due to generic increased risk of VTE with infection¹⁹ or due to a specific pro-thrombotic state caused by or resulting from COVID-19 infection. The reports of acute coronary syndromes with unobstructed coronary arteries and thrombotic gastrointestinal complications in COVID-19 patients lend weight to the latter. The question whether microvascular pulmonary arterial occlusion is responsible for some of the clinical deterioration in patients with COVID-19 is a hot topic. Whether this epiphenomenon occurs in the absence of macrovascular disease with PE and/or deep venous thrombosis is uncertain, but likely. The role of empirical anticoagulation in some COVID-19 subgroups is being considered, but anecdotal reports of spontaneous haemorrhage, including sub-arachnoid haemorrhage, make decision-making challenging.

Point-of-care ultrasound could help in potentially two situations¹: Doppler ultrasound of the deep veins of the legs to assess for deep-vein thrombosis or² focussed right-heart echocardiography to assess right ventricular findings in acute PE; however, the former will not answer the question of microvascular disease and the latter may be confounded by concomitant acute or chronic lung disease. In the presence of ground glass and/or consolidation, ventilation–perfusion (V/Q) assessment for macro/microvascular pulmonary arterial disease will be limited. CTPA will depict PE out to the subsegmental level, providing imaging quality is sufficient. The recent study of Chen *et al.*²⁰ comprising 1,008 patients admitted to hospital with COVID-19 pneumonia, reported the findings in 25 patients who underwent CTPA. Acute PE was found in 10/25 with a high D-dimer level in those with PE compared to those without. Traditional ancillary imaging findings of microvascular disease, for example, in the context of chronic thromboembolic disease, may be challenging to assess reliably in the context of concomitant viral pneumonia and/or acute respiratory distress. Dual-energy CTPA has been demonstrated to predict regional perfusion heterogeneity in a porcine model of acute lung injury,²¹ but it is uncertain whether it would accurately detect microvascular pulmonary arterial occlusion. Practically speaking, consideration will need to be given to the use of intravenous iodinated contrast medium in patients at risk of acute kidney injury (AKI). Although there will be understandable concerns of contrast-induced nephropathy, a recent meta-analysis of 28 studies and 107,335 participants found no significant differences in AKI, need for renal replacement therapy, or all-cause mortality between patients receiving contrast-enhanced CT versus those receiving unenhanced CT, suggesting other patient and illness factors, rather than contrast material are likely to contribute to AKI.²² It should be noted that patients with COVID-19, or suspected COVID-19, requiring high-flow nasal cannula oxygen delivery or non-invasive ventilation pose a risk of aerosolisation.²³ Transferring such patients to radiology departments for CTPA would have implications for infection control and cleaning as per local institutional policy. At the time of writing, we therefore can only endorse CTPA imaging where

the result will alter clinical management and it is considered safe to administer intravenous contrast media. Nevertheless, it is acknowledged that the threshold for requesting and performing CTPA may be lower than originally thought, especially in cases with “disproportionate” hypoxia, and potentially even in unexpectedly very high D-dimers (>5,000 ng/ml) or a new “significant rise” in D-dimer.

Percutaneous lung biopsy in COVID-19

The Society of Interventional Radiology recommends the use of appropriate personal protective equipment for interventional radiologists “performing any aerosol-generating procedure (i.e., any procedure that is likely to induce coughing)”.²⁴ BSTI endorses the classification of percutaneous lung biopsy (PLB) as a potential aerosol-generating procedure due to the increased risk of patient coughing during and immediately after the procedure. We would also suggest a period of 7 days of self-isolation after an uncomplicated PLB in order to mitigate the risk of a COVID-19 naive patient acquiring COVID-19 infection in the post-procedure period; it is felt that this pragmatic advice potentially reduces the risk of COVID-19 pulmonary infection as an insult on top of any small post-biopsy pneumothorax or perilesional haemorrhage. It should also be recognised that ambulatory lung biopsy^{25,26} permits PLB to be performed in an entirely outpatient setting. This may allow continuation of lung cancer diagnostic work-up at a time when bed availability is likely to be scarce and liable to risk of nosocomial COVID-19 transmission. The potential introduction of serology-based COVID-19 testing may be useful in the triage of PLB requests by indicating those patients that may have immunity from earlier, mild COVID-19 infection.

Conclusion

The management strategies in COVID-19 patients continue to evolve. Despite the vast numbers of worldwide cases, it remains difficult to standardise care and guidelines. New challenges will emerge and, with them, further dilemmas are faced. Radiologists should be aware of the current issues of potential increased thrombotic risk in COVID-19, not only affecting the pulmonary arteries but also other organs. Although the role for CTPA remains unclear, it is quite possible that the threshold for considering it will be lower than originally anticipated. Through the collaboration of BSTI with NHSX, there will be a refined dataset of imaging, clinical parameters, and outcome measures that can hopefully answer some of these questions.

Conflict of interests

The authors declare no conflict of interest.

Acknowledgements

J.J. reports fees from Boehringer Ingelheim and Roche unrelated to the current submission and is supported by a Clinical Research Career Development Fellowship 209553/Z/17/Z from the Wellcome Trust. A.N. reports non-financial support from AIDENCE BV.

Appendix A. Supplementary data

Supplementary data to this article can be found online at <https://doi.org/10.1016/j.crad.2020.04.002>.

References

- Lu H, Stratton CW, Tang Y. The Wuhan SARS-CoV-2—what’s next for China. *J Med Virol* 2020;1–2. <https://doi.org/10.1002/jmv.25738>.
- Rodrigues JCL, Hare SS, Edey A, et al. An update on COVID-19 for the radiologist: a British society of Thoracic Imaging statement. *Clin Radiol* 2020 May;75(5):323–5.
- Hare SS, Rodrigues JCL, Jacob J, et al. A UK-wide British Society of Thoracic Imaging COVID-19 imaging repository and database: design, rationale and implications for education and research. *Clin Radiol* 2020 May;75(5):326–8.
- Nair A, Rodrigues JCL, Hare S, et al. A British Society of Thoracic Imaging statement: considerations in designing local imaging diagnostic algorithms for the COVID-19 pandemic. *Clin Radiol* 2020 May;75(5):329–34.
- NHS England. *Specialty guides for patient management during the coronavirus pandemic*. 2020.
- The British Society of Thoracic Imaging. COVID-19 BSTI reporting templates. Available at: <https://www.bsti.org.uk/covid-19-resources/covid-19-bsti-reporting-templates/>. [Accessed 17 March 2020].
- Wong HYF, Lam HYS, Fong AH-T, et al. Frequency and distribution of chest radiographic findings in COVID-19 positive patients. *Radiology* 2019;201160.
- Hope M, Raptis C, Shah A. A role for CT in COVID-19? What data really tell us so far. *Lancet* 2020;6736(20):30728.
- Wang Y, Dong C, Hu Y, et al. Temporal changes of CT findings in 90 patients with COVID-19 pneumonia: a longitudinal study. *Radiology* 2020:200843.
- Yang W, Yan F. Patients with RT-PCR confirmed COVID-19 and normal chest CT. *Radiology* 2020:200702.
- Ai T, Yang Z, Hou H, et al. Correlation of chest CT and RT-PCR testing in coronavirus disease 2019 (COVID-19) in China: a report of 1014 cases. *Radiology* 2020:200642.
- Public Health England. Testing for coronavirus (COVID-19) will increase to 25,000 a day. GOV.UK. Available at: <https://www.gov.uk/government/news/testing-for-coronavirus-covid-19-will-increase-to-25-000-a-day>. [Accessed 5 April 2020].
- Hare S, Rodrigues J, Nair A, et al. Lessons from the frontline of the COVID-19 outbreak. *BMJ*. 20 March. Available at: <https://blogs.bmj.com/bmj/2020/03/20/lessons-from-the-frontline-of-the-covid-19-outbreak/> (accessed 5 April 2020).
- Tavare AN, Braddy A, H J, et al. *Managing high clinical suspicion COVID-19 inpatients with negative RT-PCR: a pragmatic and limited role for thoracic CT*. Thorax Press; 2020.
- Lei S, Jiang F, Su W, et al. Clinical characteristics and outcomes of patients undergoing surgeries during the incubation period of COVID-19 infection. *EClinicalMedicine* 2020:100331 <https://linkinghub.elsevier.com/retrieve/pii/S2589537020300754>.
- The Royal College Of Surgeons Of Edinburgh. Intercollegiate general surgery guidance on COVID-19 UPDATE. Available at: <https://www.rcsed.ac.uk/news-public-affairs/news/2020/march/intercollegiate-general-surgery-guidance-on-covid-19-update> (accessed 5 April 2020).
- Inui S, Fujikawa A, Jitsu M, et al. Chest CT findings in cases from the cruise ship “Diamond Princess” with coronavirus disease 2019 (COVID-19). *Radiol Cardiothorac Imaging* 2020;2(2):e200110 <http://pubs.rsna.org/doi/10.1148/ryct.2020200110>.

18. Pan F, Ye T, Sun P, *et al.* Time course of lung changes on chest CT during recovery from 2019 novel coronavirus (COVID-19) pneumonia. *Radiology* 2020;200370.
19. Grimnes G, Isaksen T, Tichelaar YIGV, *et al.* Acute infection as a trigger for incident venous thromboembolism: results from a population-based case-crossover study. *Res Pract Thromb Haemost* 2018;2(1):85–92.
20. Chen J, Wang X, Zhang S, *et al.* Findings of acute pulmonary embolism in COVID-19 patients. Available at: <https://ssrn.com/abstract=3548771>; 2020 (accessed).
21. Kay FU, Beraldo MA, Nakamura MAM, *et al.* Quantitative dual-energy computed tomography predicts regional perfusion heterogeneity in a model of acute lung injury. *J Comput Assist Tomogr* 2018;42(6):866–72.
22. Aycock RD, Westafer LM, Boxen JL, *et al.* Acute kidney injury after computed tomography: a meta-analysis. *Ann Emerg Med* 2018;71(1):44–53.
23. Cheung JC-H, Ho LT, Cheng JV, *et al.* Staff safety during emergency airway management for COVID-19 in Hong Kong. *Lancet Respir Med* 2020;8(4):e19.
24. Society of Interventional Radiology. Aerosol generating procedures clinical notification. Available at: <https://www.sirweb.org/practice-resources/covid-19-resources/covid-19-clinical-notification-3-26-20/>. [Accessed 5 April 2020].
25. Tavare AN, Creer DD, Khan S, *et al.* Ambulatory percutaneous lung biopsy with early discharge and Heimlich valve management of iatrogenic pneumothorax: more for less. *Thorax* 2016;71(2):190–2.
26. Barnett J, Belsey J, Tavare AN, *et al.* Pre-surgical lung biopsy in management of solitary pulmonary nodules: a cost effectiveness analysis. *J Med Econ* 2019;22(12):1307–11.

- S. Hare^{a,†}, J.C.L. Rodrigues^{b,†}, A. Nair^c, J. Jacob^{d,e}, S. Upile^f, A. Johnstone^g, R. Mcstay^h, A. Edeyⁱ, G. Robinson^{b,*}
- ^a Department of Radiology, Royal Free London NHS Trust, London, Pond Street, London NW3 2QJ, UK
- ^b Department of Radiology, Royal United Hospitals Bath NHS Foundation Trust, Combe Park, Bath BA1 3NG, UK
- ^c Department of Radiology, University College London Hospital, 235 Euston Road, London NW1 2BU, UK
- ^d Department of Respiratory Medicine, University College London, London, NW1 2BU, UK **Q1**
- ^e Centre for Medical Image Computing, University College London, London NW1 2BU, UK
- ^f School of Radiology, Manchester Postgraduate Deanery, UK **Q23**
- ^g Department of Radiology, Leeds Teaching Hospitals NHS Trust, Leeds General Infirmary, Great George Street, Leeds LS1 3EX, UK
- ^h Department of Radiology, Freeman Hospital, Newcastle upon Tyne Hospitals NHS Foundation Trust, Freeman Road, Newcastle upon Tyne, NE7 7DN, UK
- ⁱ Department of Radiology, Southmead Hospital, North Bristol NHS Trust, Southmead Road, Bristol BS10 5NB, UK
E-mail address: grobins1@nhs.net (G. Robinson)

†
These authors are joint first authors.

* Guarantor and correspondent: G. Robinson, Department of Radiology, Royal United Hospitals Bath NHS Foundation Trust, Combe Park, Bath, BA1 3NG, UK. **Q4**